

Extraction of swallowed chicken bone penetrating the esophageal walls after 10 days

Reza Bagheri^{1*}

¹Thoracic Surgeon, Lung Diseases Research Center, Mashhad University of Medical Sciences, Mashhad, Iran.

ARTICLE INFO

Article type:
Images in Cardiothoracic Surgery

Article history:
Received: 15 April 2019
Revised: 15 May 2019
Accepted: 30 May 2019

Keywords:
Foreign Bodies
Esophageal Perforation
Endoscopy
Treatment

ABSTRACT

Introduction: A 23-year-old male referred with a history of chicken bone swallowing a week ago (Figure 1). Endoscopy was performed at our center and a chicken bone was found penetrating the esophageal walls (Figure 2). The patient was managed successfully using flexible endoscopy and the chicken bone was removed.

► Please cite this paper as:

Reza Bagheri. Extraction of swallowed chicken bone penetrating the esophageal walls. J Cardiothorac Med. 2019; 7(2):458-459.

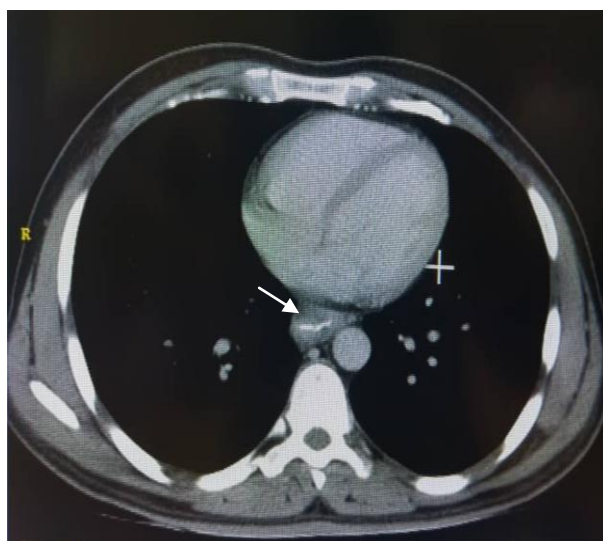


Figure 1. Computed tomography (CT) with a sharp chicken bone retrieved from the esophageal wall

*Corresponding author: Reza Bagheri, Lung Diseases Research Center, School of Medicine, Mashhad University of Medical Sciences, Mashhad, Iran. Tel and Fax: +985138402972; Email: Bagherir@mums.ac.ir

© 2019 *mums.ac.ir* All rights reserved.

This is an Open Access article distributed under the terms of the Creative Commons Attribution License (<http://creativecommons.org/licenses/by/3.0>), which permits unrestricted use, distribution, and reproduction in any medium, provided the original work is properly cited.

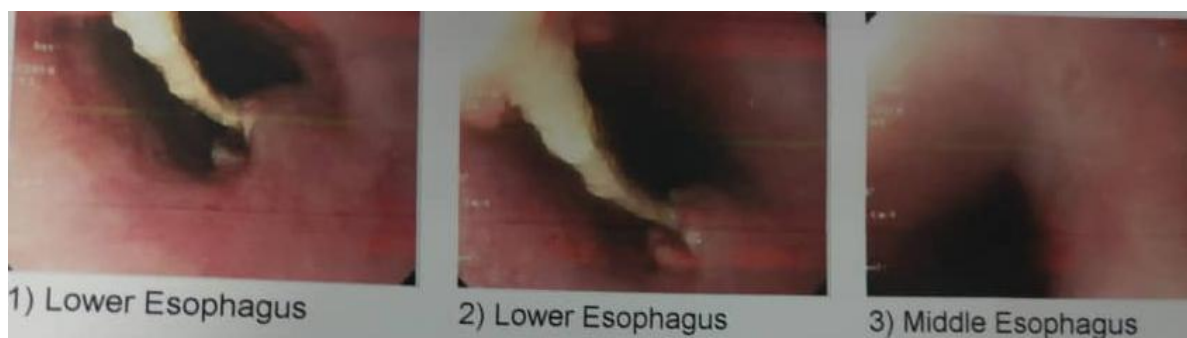

Figure 2. Endoscopic image showing a sharp chicken bone penetrating the esophageal walls

Financial support and sponsorship:

The present study received no financial support.

Conflicts of interest:

The authors declare that there is no conflict of interest.