

## Very large hydatid cyst in a 17-year-old female

Reza Bagheri<sup>1\*</sup>

<sup>1</sup>Thoracic Surgeon, Lung Diseases Research Center, Mashhad University of Medical Sciences, Mashhad, Iran.

### ARTICLE INFO

Article type:

Images in Cardiothoracic Surgery

Article history:

Received: 15 April 2019

Revised: 15 May 2019

Accepted: 30 May 2019

Keywords:

Hydatid Cyst

Hemithorax

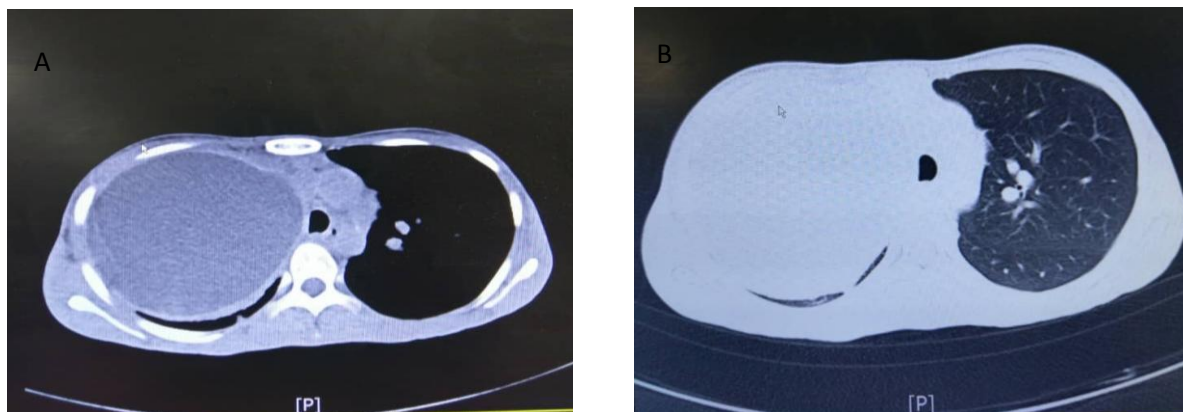
Outcomes

### ABSTRACT

**Introduction:** A 17-year-old female presented with dyspnea, chest pain, and a very large cyst occupying the entire right hemithorax Figure 1(A, B). The patient is under full cyst extending to membrane Figure 2 (A, B).

► Please cite this paper as:

Reza Bagheri. Very large hydatid cyst in a 17-year-old female. J Cardiothorac Med. 2019; 7(2):460-461.

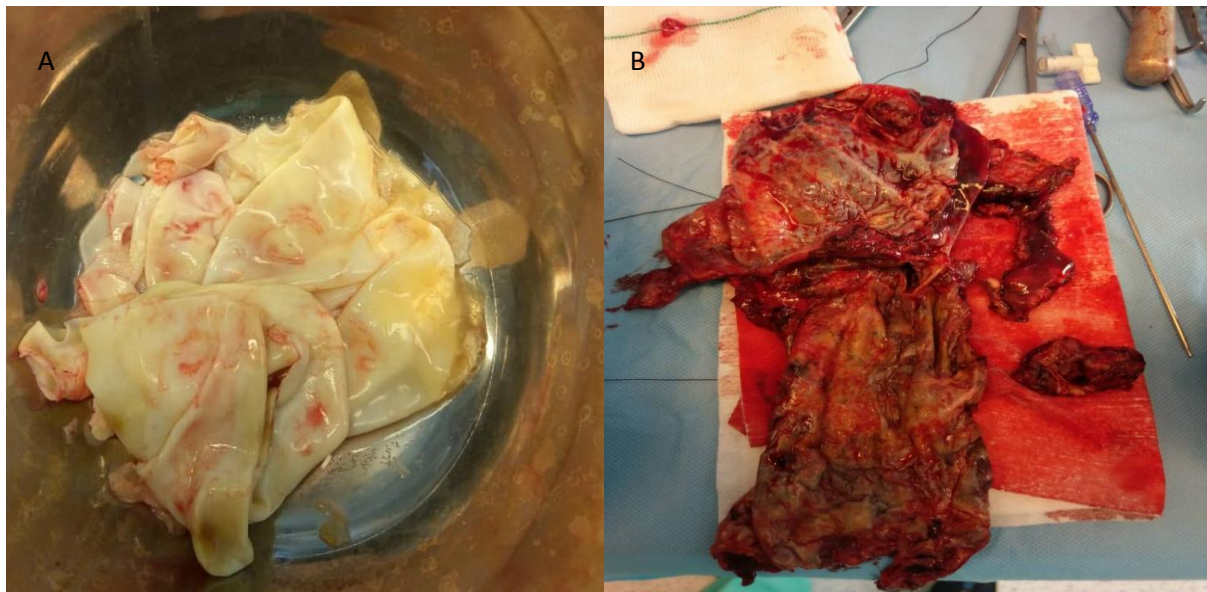


**Figure 1 (A, B):** Computed tomography scan and chest x-rays showing very large hydatid cyst

\*Corresponding author: Reza Bagheri, Lung Diseases Research Center, School of Medicine, Mashhad University of Medical Sciences, Mashhad, Iran. Tel and Fax: +985138402972; Email: [Bagherir@mums.ac.ir](mailto:Bagherir@mums.ac.ir)

© 2019 [mums.ac.ir](http://mums.ac.ir) All rights reserved.

This is an Open Access article distributed under the terms of the Creative Commons Attribution License (<http://creativecommons.org/licenses/by/3.0>), which permits unrestricted use, distribution, and reproduction in any medium, provided the original work is properly cited.



**Figure 2 (A, B):** Membrane discharged and removed the cystic fibrosis (PRESIS) completely

### **Financial support and sponsorship**

The present study received no financial support.

### **Conflicts of interest**

The authors declare that there is no conflict of interest.