

Cardiac arrhythmia due to ledipasvir/sofosbuvir iranian counterpart, commercially named as Ledibiox: A case report

Alireza Heidari Bakavoli¹, Alireza Ghodsi², Alireza Omranzadeh², Moniba Bijari², Sara Hosseini^{1*}

¹ *Cardiologist, Cardiovascular Research Center, Mashhad University of Medical Sciences, Mashhad, Iran*

² *Medical student, Student Research Committee, Faculty of Medicine, Mashhad University of Medical Sciences, Mashhad, Iran*

ARTICLE INFO

Article type:
Case report

Article history:

Received: 02 June 2020
Revised: 10 July 2020
Accepted: 20 August 2020

Keywords:

Arrhythmia
Cardiac
ledipasvir/sofosbuvir
Ledibiox

ABSTRACT

Sofosbuvir is an antiviral drug that entirely revolutionized the treatment of hepatitis C. This drug has an Iranian commercial brand, which is known as Ledibiox. Several adverse events have been reported with this drug, including syncope, pancolitis, and exacerbated pulmonary arterial hypertension; however, arrhythmia rarely has been described through the literature. Here, we report a 40-year-old Caucasian man who presented with chest pain, tachycardia, blurred vision, and severe headache; whose electrocardiography showed an atrial tachycardia along with a block. It seems that Sofosbuvir toxicity can cause arrhythmia, and the drug prescription should be halted in this situation.

► Please cite this paper as: Heidari Bakavoli, A., Ghodsi, A., Omranzadeh, A., Bijari, M., Hosseini, S. Cardiac arrhythmia due to ledipasvir/sofosbuvir Iranian counterpart, commercially named as Ledibiox: A case report. *Journal of Cardio-Thoracic Medicine*, 2020;(3):679-683

Introduction

The introduction of sofosbuvir, as an oral nucleotide polymerase inhibitor, made considerable changes in the treatment of hepatitis C virus (HCV), in early 2014. The treatment period is usually 12 weeks for Sofosbuvir and ribavirin/interferon combination therapy or 24 weeks for Sofosbuvir monotherapy (1). This drug is commercially known as Ledibiox in Iran

(2). Cases of syncope, pancolitis, exacerbated pulmonary arterial hypertension, and Fanconi syndrome have been reported with Ledibiox treatment. Although its side effects are less common than the peginterferon, the adverse effects of the sofosbuvir containing regimen include fatigue, headache, nausea, and neutropenia. Also, drug interaction has been reported in combination with anti-arrhythmic drugs,

*Corresponding author: Sara Hossein. Cardiovascular Research Center, Mashhad University of Medical Sciences, Mashhad, Iran. Tel and Fax: +985138400000, E-mail: hosseinis9211@gmail.com

© 2016 mums.ac.ir All rights reserved.

This is an Open Access article distributed under the terms of the Creative Commons Attribution License (<http://creativecommons.org/licenses/by/3.0>), which permits unrestricted use, distribution, and reproduction in any medium, provided the original work is properly cited.

causing dramatic bradycardia (3). Thus, arrhythmia can be considered as a component of sofosbuvir toxicity.

The primary mechanism of arrhythmia is dependent on the reentry, triggered activity, and automaticity. Arrhythmias are often categorized according to their basic mechanisms. The reentry process is usually associated with the block and slow conduction areas, and it is verified by the existence of manifest or concealed entrainment. The initiation and termination of enhanced or abnormal automaticity are not induced with programmed electrical stimulation but can be triggered with intravenous isoproterenol (4). As a type of arrhythmia, atrial tachycardia falls into two classes: Focal atrial tachycardia and Macroreentrant atrial tachycardia. Atrial tachycardia with a block is another prototype of arrhythmia, which is a rare outcome of digitalis intoxication and is usually a sign of poor prognosis. The condition is manifested as a hybrid of both atrial tachycardia, and atrial flutter and in some cases, advanced degrees of heart block (5). The aim of our study is to report a rare case of arrhythmia induced after a period of oral consumption of Ledibiox which is a mixture of Ledipasvir (90 mg) and Sofosbuvir (400 mg).

Case presentation

A 40-year-old Caucasian man presented with chest pain, tachycardia, blurred vision, and severe headache. The patient reported a history of thalassemia and a 20-year-old HCV infection due to recurrent factor 5 and 8 infusions for hemophilia treatment. Also, the patient had a past medical history of two six-month periods of interferon therapy. Moreover, he received a course of Ledibiox treatment once daily, three months ago. Each Ledibiox tablet has 90 mg of Ledipasvir and 400 mg of Sofosbuvir. He also stated exertional dyspnea, malaise, and vertigo after two months of Ledibiox treatment. He denied

abuse of any kind of drug, tobacco, alcohol, or high dose caffeine consumption. Also, drug history was devoid of any over the counter drug consumption, herbal medication or regular daily drug consumption. Past medical history was negative for diabetes, hypertension, thyroid dysfunction, and any structural or functional heart problems. Also, his family history had nothing prominent in to be suspicious of heart problems. The patient also had no history of any kind of surgical procedures, especially heart surgery.

Physical examination had nothing significant to approach any diseases. The auscultation and percussion of the lung field were clear. Also, the jugular vein pulsation was normal, and there was no edema in the whole body. After admission to the emergency room, a 12-lead electrocardiography (ECG) was conducted for the patient. His ECG showed a heart rate of 125 beats per minute (bpm) with regular narrow QRS complexes and an atrial tachycardia with a block (Figure 1). Blood laboratory assessment had no clue for any kind of underlying problems like impaired thyroid function, imbalanced serum electrolytes, elevated serum troponin, low blood glucose level, or any kind of anemia. After discharge, Holter monitoring was conducted that demonstrated Mobitz I (Wenkebach) block (Figure 2).

The condition was considered as a side effect of Ledibiox; therefore, after a consultation with Gastrointestiniologist and Infectious disease specialist, Ledibiox was ceased. At the end of a six-month follow-up, all the patient's symptoms subsided. Also, ECG assessment showed regular sinus rhythm (Figure3).

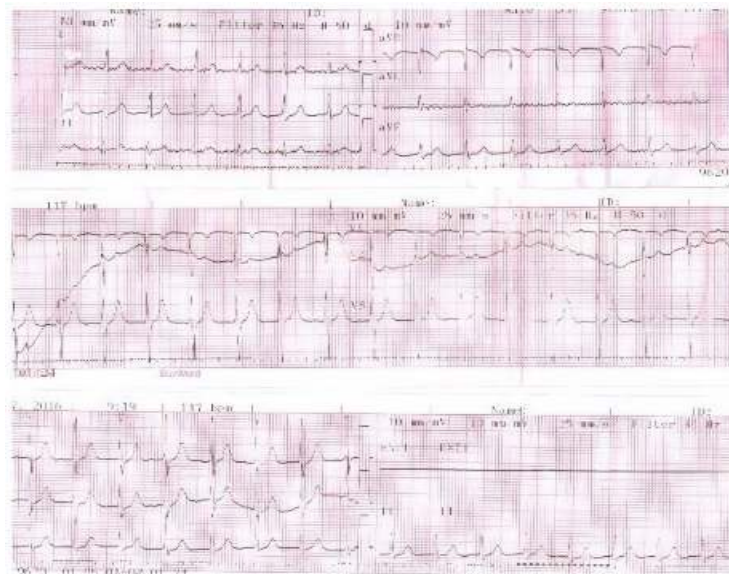


Figure 1. Twelve-lead electrocardiogram at the initial presentation at an emergency

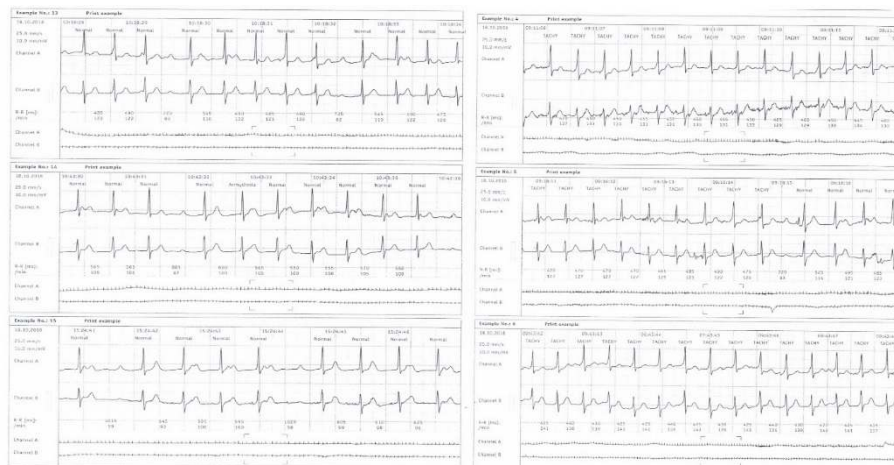


Figure 2. Holter monitoring results

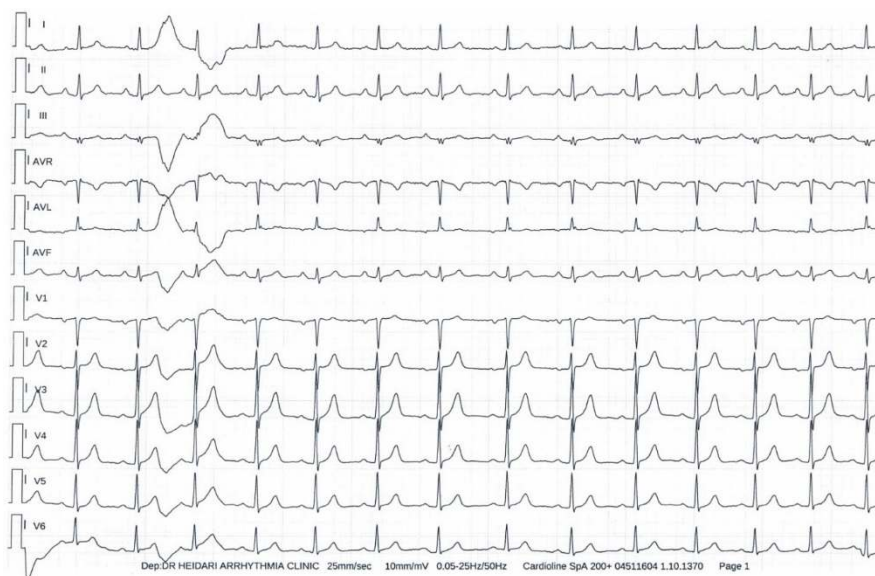

Figure 3. Electrocardiogram after Ledibiox withdrawal

Discussion

As many as 170 million people suffer from chronic HCV infection all around the world. The sustained virologic response is defined as amounts of HCV RNA levels lower than detectable amounts after 12 weeks of the end of the treatment and is achieved in 90% of patients treated with sofosbuvir. Therefore, sofosbuvir has revolutionized the management of chronic HCV infection. Several thousands of people have been treated with this drug so far, but our knowledge about sofosbuvir still needs to be grown (1). Daily single dose regimen of ledipasvir/sofosbuvir is approved in the USA, and its oral forms have good tolerability in HCV patients. American Association for the Study of Liver Disease (AASLD) and the Infectious Diseases Society of America (IDSA) have proposed a twelve-week regimen of ledipasvir and sofosbuvir treatment as a choice for treatment-naïve HCV patients with 1a and 1b genotypes (6). Sofosbuvir containing regimen as a direct antiviral agent has increased the rate and reduced the period of treatment. A study on 741 patients in phase 2 trial of the sofosbuvir showed a proper safety for the drug itself or in combination with ribavirin or ribavirin and peginterferon. Moreover, another study on 514 HCV cases proposed sofosbuvir as an efficient and well-tolerated drug (7). However, the incidence of sofosbuvir adverse effects in clinical practice is higher than the proposed incidence in the clinical trials, and even its efficacy is lower than that of clinical studies (8). Bagate et al. published a case-series of five cases, who developed severe arrhythmia due to the sofosbuvir. The patients' ages ranged from 50 to 75, and there was HIV co-infection in two cases. All cases developed arrhythmia within the first days of initiating sofosbuvir. Three case also showed conductive disorders and pacemaker was implanted for all three cases, but none of them became pacemaker-dependent after drug cessation. Also, a case of arrhythmia relapse was seen after reintroducing the drug to one of the cases (9). Another report in 2016 mentioned two chronic HCV-infected middle-aged males with syncope due to sofosbuvir. One of the cases had a syncopal attack 21 days after starting treatment of hepatitis C with

sofosbuvir 400 mg/day plus ribavirin 1000 mg/day. The other case had an episode of syncope 9 days after treatment with interferon, ribavirin, and sofosbuvir (10). Our study also reported a case of ledibiox-induced arrhythmia as an adverse drug effect for the Iranian brand of sofosbuvir. The condition easily resolved after holding the treatment; however, the manufacturers must take this side effect into consideration.

Conclusion

There seems to be a kind of cardiac toxicity for ledibiox and the patients should be followed for further side-effect development with this regard. Arrhythmia, as a rare side-effect of the drug, should be taken into consideration, and drug cessation is the best way to achieve the normal sinusoidal heart rhythm. It seems that the complication is usually benign, but further investigation is needed to prove this finding.

Conflicts of interest

The authors declared no conflicts of interest regarding this manuscript.

References

1. Ruane PJ, Ain D, Stryker R, Meshrekey R, Soliman M, Wolfe PR, et al. Sofosbuvir plus ribavirin for the treatment of chronic genotype 4 hepatitis C virus infection in patients of Egyptian ancestry. *J Hepatol*. 2015;62(5):1040-6.
2. Merat S. Hepatitis C Virus Guideline in Iran. *Govaresh*. 2017;22(3):182-5.
3. In brief: severe bradycardia with sofosbuvir and amiodarone. *Med Lett Drugs Ther*. 2015;57(1466):58.
4. Gillette P, Crawford F, Zeigler V. Mechanisms of atrial tachycardias. *Card Electrophysiol*. 1990:559-63.
5. Lown B, Marcus F, Levine HD. Digitalis and Atrial Tachycardia with Block. *N Eng J Med*. 1959;260(7):301-9.
6. Diseases AAftSoL, America IDSo. Recommendations for testing, managing, and treating hepatitis C. 2014.
7. Kowdley K, Hassanein T, Gane E, Hyland R, Ma J, Symonds W, et al. 842 sofosbuvir safety and tolerability in 741 patients treated for up to 24 weeks. *J Hepatol*. 2013;58:S345.
8. Gordon SC, Muir AJ, Lim JK, Pearlman B, Argo CK, Ramani A, et al. Safety profile of boceprevir and telaprevir in chronic hepatitis C: real world experience from HCV-TARGET. *J hepatol*. 2015;62(2):286-93.
9. Bagate F, Lazarus A, Fontaine H, Pecriaux C, Sogni P, Pol S, et al. 0428: Cardiac arrhythmia after initiation of sofosbuvir-including regimen

in patients with chronic hepatitis C virus infection. *Arch Cardiovasc Dis Suppl.* 2016;8(1):76.

10. Lashen S, Sanhoury M. Syncope Following Sofosbuvir Therapy for Chronic Hepatitis C: A Report of Two Cases. *J Liver Res Disord Ther.* 2016;2(4):00032.