

Aortic Valve replacement with Reduction Aortoplasty with Mesh Prosthesis in 75 years old with Sever aortic Regurgitation with Aortic Aneurysm

Hamid Hoseinikhah¹, Mohammad AbbasiTashnizi¹, Omid Javdanfar², Aliasghar Moeinipour^{*4}

¹ Cardiac Surgeon, Department of Cardiac Surgery, Faculty of Medical Science. Mashhad University of Medical Sciences, Mashhad, Iran.

²Resident of Cardiac Surgery, Department of Cardiac Surgery, Faculty of Medical Science, Mashhad University of Medical Sciences, Mashhad, Iran

ARTICLE INFO

Article type:
Case report

Article history:
Received: 25 May 2020
Revised: 21 August 2020
Accepted: 10 Sept 2020

Keywords:
Aortic Aneurysm
Aortic Surgery
Aortic Valve

ABSTRACT

Although classic and standard procedure for patients with ascending Aorta aneurysm with Sever aortic Regurgitation is Bentall surgery but in some selected cases this complex surgery was not performed with different reason like advanced age and coexisting comorbidity involving renal and hepatic and lung Function. In our cases 75 years old man with chronic renal failure (Cr= 3.2) who was known case of sever aortic Regurgitation and Ascending Aortic Aneurysm with 5.5 diameter. Replacement of Aortic Valve with Biologic Prosthesis Aortic Valve and Reduction Aortoplasty with Mesh prosthesis was done successfully with good result with early follow up.

► Please cite this paper as: Hoseinikhah, H., Abbasi Teshnisi, M., Javdanfar, O., moeinipour, A. Aortic Valve replacement with Reduction Aortoplasty with Mesh Prosthesis in 75 years old with Sever aortic Regurgitation with Aortic Aneurysm. Journal of Cardio-Thoracic Medicine, 2020; (3):662-665

Introduction

Aortic Aneurysm is senile and degenerative process. Increase in Size of Aorta and other major arteries are seen after 5 decades of life that

Decision for replacement of aneurysmal ascending Aorta depended to Size of ascending Aorta and also rate of progression the size of Aorta each year (1-3). Anatomically we can divide Thoracic Aorta to three parts that named Ascending Aorta, Aortic Arch, descending Aorta. Dilation and Expansion of Aortic Lumen can be occurred

in any of these three segment or can be involved more than one part in same time (4). By definition Aortic Aneurysm referred to localized dilation of the Thoracic aorta more than 50% of predicted size or in more Simple definition it is Called Aortic Aneurysm when Size Aortic Aneurysm more than 1.5 larger than Normal Ratio (5). Like other Great Vessel, Thoracic Aorta have three Layer consist of Intima, Media, Adventia that in Case of Aortic Aneurysm With advanced age , we see cystic medial degeneration that consist of fragmentation

*Corresponding author: Aliasghar Moeinipour, Department of Cardiac Surgery, Faculty of Medical Science. Mashhad University of Medical Sciences, Iran. Tel & Fax: +98513-1802321, E-mail: moeinipoora1@mums.ac.ir
© 2016 mums.ac.ir All rights reserved.

This is an Open Access article distributed under the terms of the Creative Commons Attribution License (<http://creativecommons.org/licenses/by/3.0>), which permits unrestricted use, distribution, and reproduction in any medium, provided the original work is properly cited.

of elastic fiber, smooth muscle dropout that can cause in stiffness and weakening of the aortic wall that finally this process can be continued to Formation of Thoracic Aortic Aneurysm(6-8).

There is no medical treatment for Aortic Aneurysm although some drugs like Beta Blocker and Statin show that decrease the rate of Progression of Aortic Size. The only treatment for Aortic Aneurysm is Surgical Intervention that is recommended when Ascending Aorta Size reach to 5 to 5.5 cm. (8)

At the time of Surgery, classic procedure is resection of diseased enlarged Vessel and Replacement of segment with Vascular Prosthesis. When Aortic Aneurysm involve Ascending Aorta and Aortic Root, sever dilation of Aortic Wall steadily can destroy the Aortic Valve and Lead to Aortic Valve Regurgitation and Chronic Heart Failure without proper Intervention.. In such Cases Cardiac Surgeon should chose a procedure that replaced Disease Aortic Valve and also enlarged Ascending Aorta. And replace them with Composite Graft consist of Mechanical Aortic Valve and Dacron Aortic Tube Graft.

Case report

A 75 years old man was referred to us in Department of cardiac surgery of Ghaem Hospital of Mashhad University of medical sciences who known cases of Sever AR and Ascending Aortic Aneurysm that size in Aortic root was 5 and ascending aorta after STJ until proximal of Aortic Arch was 5.5 cm after Aortic Arch had diameter near normal size. Patient was sever COPD and also renal function test of him was increased significantly (BUN= 75, Cr= 3.2)

Also standard and classic procedure in such cases is Bentall procedure that consist of replacement of Aortic valve and also Ascending aorta with composite Graft (Mechanical Aortic Valve & Dacron tube Graft) and Reimplantaion of coronary arteries to Tube Graft, but in this case because of advanced age and present comorbidities (COPD , CRF) despite of Bentall surgery we decide to replacement of diseased Aortic Valve with Biologic Aortic Valve prosthesis (No: 23) and used a piece Mesh Prosthesis with 8*8Cm that completely encircled around Ascending Aorta. This Mesh was

secured with fine 2/0 Prolen Suture to adventia of ascending Aorta.

Weaning of patient from was performed easily and no significant Bleeding was noticed. Patient was discharged from hospital 6 days after surgery after reaching to Target of INR and until 6 months of close follow up in good condition. Trans thoracic Echocardiography examination show good result of both Mechanical Aortic Valve and also Mesh prosthesis. Mechanical Aortic Valve had good hemodynamic data and no paravalvular leakage.

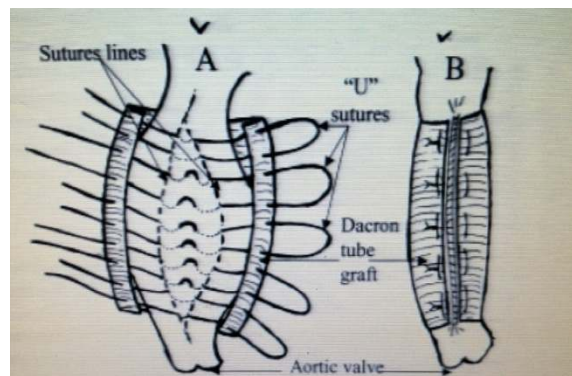


Figure 1: Schematic View of Reduction Aortoplasty with Mesh.

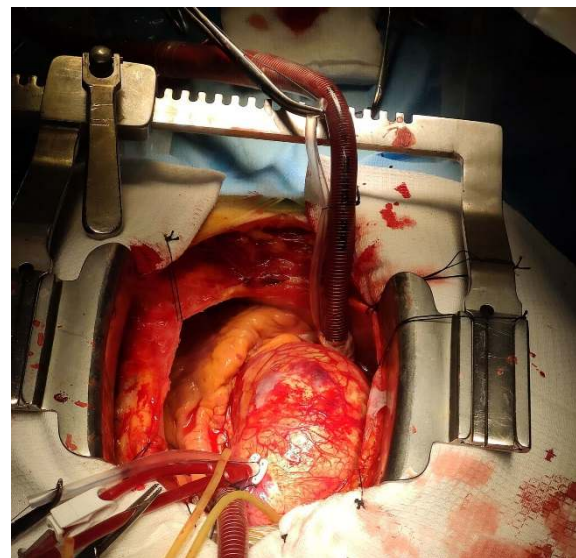


Figure 2: Ascending Aortic Aneurysm

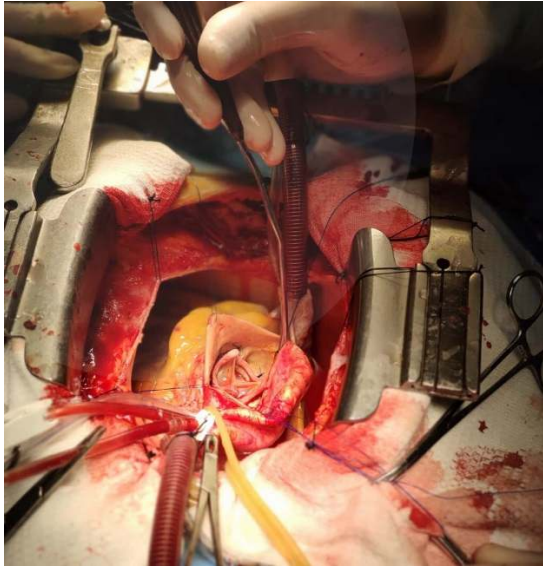


Figure 3: Inside of Aortic Aneurysm after AVR with Biologic Prosthesis

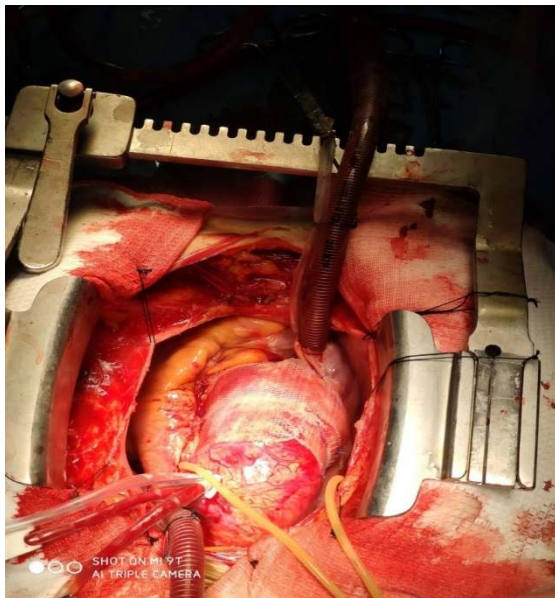


Figure 4: Reduction Aortoplasty after wrapping with Mesh around aortic Wall

Discussion

The risk of expansion of Ascending aorta in case of aortic aneurysm is rupture of aorta that cause exsanguinating bleeding into left hemi thorax or pericardial space with tamponade result or pseudo aneurysm formation of aorta that finally all of them are very dangerous with important potential for death of patient. In classic Bentall procedure that whole of aortic valve and aortic root and Ascending aorta is replaced with prosthesis the risk of rupture of aorta is eliminated but when a piece of Mesh prosthesis is used

around enlarged Aorta, short time after insertion of it, Mesh is adherent tightly to Aorta that minimize the risk of future rupture and bleeding of aorta. Replacement of the ascending aorta with avascular prosthetic is the best surgical option but external wrapping of the aorta is a simple, fast, and effective option for minimizing the risk of further rupture ascending aortic aneurysms(8-11).

This procedure although is not recommended in all cases as standard procedure but also in selected cases that cardiac surgeon afraid of complex surgery and longtime of Cardiopulmonary Bypass Abdi Aortic Clamp, this simple procedure that consist of replacement of Aortic Valve for Sever AR and insertion of Mesh Prosthesis around the Aorta can be used with good results. (12).The results of this study show that Aortoplasty with Prosthesis for treating ascending aortic Aneurysm is a simple & safe & fast alternative option to replace of diseased Aorta with Tube Graft. To avoid future redilatation after this procedure, Cardiac surgeon should select only Patients with aortic size less than 6 cm as noticed by Coady and colleagues⁶ In some study Reduction Aortoplasty can Also be used in other reason of Aortic Aneurysm (except that Senile & degenerative Aortic Aneurysm) like Aortic Aneurysm in Bicuspid Aortic Valve and Marfan Syndrome with good results in Early and Late term Follow up but in very selected cases usually in advanced age of Patients and with Sever Comorbidities like Renal Failure and Hepatic Failure and COPD. This simple technique can be performed in much selected patients with that in we prefer to avoid prolonged cardiopulmonary bypass time and Ischemic Time that can increase the mortality and morbidity of Classic complex procedure. The Largest size that is possible for this simple procedure is 6cm diameter of Ascending Aorta and the risk of Failing Reduction Aortoplasty for Ascending Aorta larger than 6 cm is very High (13-15).

Conclusion

We recommended this less invasive procedure for very selected cases with Ascending Aortic Aneurysm with moderately dilated aorta (up to 6 cm) and

advanced age (usually older than 70 years old) or high-risk patients (usually with other severe Co existing Disease) in whom a short Cardiopulmonary Bypass Time and also aortic cross-clamp time is advantageous. External Wrapping with The reduction Aortoplasty have good result with minimal Mortality and Morbidity and also further progression of Aortic Size.

Conflict of interest: None declared.

References:

1. Pomianowski P., Elefteriades J.A. The genetics and genomics of thoracic aortic disease. *Ann card surg.* 2013;2:271-279
2. Wischmeijer A., Van Laer L., Tortora G., Bolar N.A., Van Camp G., Fransen E. Thoracic aortic aneurysm in infancy in aneurysms-osteoarthritis syndrome due to a novel SMAD3 mutation: further delineation of the phenotype. *Am J Med Genet A.* 2013;161A:1028-1035. [PubMed] [Google Scholar]
3. Hiratzka L.F., Bakris G.L., Beckman J.A., Bersin R.M., Carr V.F., Casey D.E., Jr. ACCF/AHA/AATS/ACR/ASA/SCA/SCAI/SIR/STS/SVM guidelines for the diagnosis and management of patients with thoracic aortic disease: executive summary: a report of the American College of Cardiology Foundation/American Heart Association Task Force on Practice Guidelines, American Association for Thoracic Surgery, American College of Radiology, American Stroke Association, Society of Cardiovascular Anesthesiologists, Society for Cardiovascular Angiography and Interventions, Society of Interventional Radiology, Society of Thoracic Surgeons, and Society for Vascular Medicine. *AnesthAnalg.* 2010;111:279-315. [PubMed] [Google Scholar]
4. Trindade P.T. Losartan treatment in adult patients with Marfan syndrome: can we finally COMPARE? *Eur. Heart J.* 2013 [PubMed] [Google Scholar]
5. Benedetto U., Melina G., Takkenberg J.J., Roscitano A., Angeloni E., Sinatra R. Surgical management of aortic root disease in Marfan syndrome: a systematic review and meta-analysis. *Heart.* 2011;97:955-958. [PubMed] [Google Scholar]
6. Coady MA, Rizzo JA, Hammond GL, et al. What is the appropriate size criterion for resection of thoracic aortic aneurysms? *J Thorac Cardiovasc Surg* 1997;113:476-91.
7. Bauer M, Grauhan O, Hetzer R. Dislocated wrap after previous reduction aortoplasty causes erosion of the ascending aorta. *Ann Thorac Surg* 2003;75:583-4
8. Robicsek F. Invited commentary: tailoring aortoplasty for repair of fusiform ascending aneurysms. *Ann Thorac Surg* 1995;59:501
9. Immer FF, Barmettler H, Berdat PA, Immer-Bansi AS, Englberger L, Krähenbühl ES, Carrel TP: Effects of deep hypothermic circulatory arrest on outcome after resection of ascending aortic aneurysm. *Ann Thorac Surg.* 2002, 74 (2): 422-425
10. Elefteriades JA: Natural history of thoracic aortic aneurysms: indications for surgery, and surgical versus nonsurgical risks. *Ann Thorac Surg.* 2002, 74 (Suppl): S1877-S1880
11. De Paulis R, Cetrano E, Moscarelli M, Andò G, Bertoldo F, Scaffa R, Tomai F, Chiariello L: Effects of ascending aorta replacement on aortic root dilatation. *Eur J Cardiothorac Surg.* 2005, 27 (1): 86-89.
12. Gill M, Dunning J: Is reduction aortoplasty (with or without external wrap) an acceptable alternative to replacement of the dilated ascending aorta?. *Interact Cardiovasc Thorac Surg.* 2009, 9 (4): 693-697.
13. Ergin MA, Spielvogel D, Apaydin A, Lansman SL, McCullough JN, Galla JD, Griep RB: Surgical treatment of the dilated ascending aorta: when and how?. *Ann Thorac Surg.* 1999, 67 (6): 1834-1839. discussion 1853-6
14. Polvani G, Barili F, Dainese L, Topkara VK, Cheema FH, Penza E, Ferrarese S, Parolari A, Alamanni F, Biglioli P: Reduction ascending aortoplasty: midterm follow-up and predictors of redilatation. *Ann Thorac Surg.* 2006, 82 (2): 586-591
15. Kamada T, Imanaka K, Ohuchi H, Asano H, Tanabe H, Kato M, Ogiwara M, Yamabi H, Yokote Y, Kyo S: Mid-term results of aortoplasty for dilated ascending aorta associated with aortic valve disease. *Ann Thorac Cardiovasc Surg.* 2003, 9: 253-256