

Atypical Radiological Findings in Patients with Hydatid Cysts of the Lung, Study of 1024 Cases

Majid Mirsadraee^{1*}, Seyed Ziaollah Haghi², Sadegh Vaziri³, Saeed Naghibi⁴, Saeed Mirsadraee⁵

¹ Pulmonologist, Medical school-Islamic Azad University, Mashhad Branch, Mashhad, Iran

² Thoracic Surgeon, Cardio- Thoracic Surgery & Transplant Research Center, Emam Reza Hospital, Faculty of Medicine, Mashhad University of Medical Sciences, Mashhad, Iran

³ General Practitioner, Zakaria Research Center, Medical School, Islamic Azad University, Mashhad Branch

⁴ Radiologist, Islamic Azad University-Mashhad branch, Mashhad, Iran

⁵ Senior clinical lecturer in radiology- Honorary consultant radiologist, Queen's Medical Research Institute, University of Edinburgh, UK

ARTICLE INFO

Article type:
Original Article

Article history:
Received: 18-Jul-2013
Revised: 5-Sep-2013
Accepted 17-Sep-2013

Keywords:
Chest Roentgenogram
Computed Tomography
Hydatid Cyst
Hydatidosis
Radiology

ABSTRACT

Introduction: The objective of this study was to give a description of the most prominent atypical radiological presentations of lung hydatidosis.

Materials and Methods: All patients diagnosed with pulmonary hydatidosis by surgical exploration were included in this study. Standard chest roentgenogram and computed tomography (CT) were evaluated before surgery for lung cysts or unknown lesions. Radiological findings were divided into two categories: 1- Typical hydatid cysts that were previously presented by imaging as a hydatid cyst in the form of an intact cyst, water lily sign and crescent sign. 2- Atypical hydatid cysts that were not similar to typical previously mentioned hydatid cysts.

Results: During a 26-year period, 1024 subjects with pulmonary hydatidosis were diagnosed and operated on. Chest X-rays (interpreted in 832 cases) showed perforated cysts in 190 (23%) and atypical findings such as mass, alveolar type infiltration, abscess and collapse in 113 (13%) patients. Seventy-nine patients had a thoracic CT scan in which atypical cysts were detected in 32 subjects (40.5%) such as: thick wall cavity in 9 patients (28%), solid masses in 7 (21%), abscesses in 6 (18%), consolidation in 3 (9%), fungus balls in 3 (9%), collapse (atelectasis) in 2 (6%) and round pneumonia in 2 (6%). Cavity was significantly more frequent in the right lung (90%) and mass-like opacity was significantly more frequent in the lower lung field (100%).

Conclusion: Hydatid cysts should be considered for most of localized radiological pictures of the lung without respect to localization, size and count of lesions.

► Please cite this paper as:

Mirsadraee M, Haghi SZ, Vaziri S, Naghibi S, Mirsadraee S. Atypical Radiological Findings in Patients with Hydatid Cysts of the Lung, Study of 1024 Cases. *J Cardiothoracic Med.* 2013;1(3):95-99.

Introduction

Hydatid cysts of the lung (lung hydatidosis) are endemic in rural areas of the Middle East and are

commonly caused by the larvae of the *Echinococcus granulosus*(1).

Parasite larvae that reach the lung usually pass

*Corresponding author: Majid Mirsadraee, No: 80, 15th Kosar, Kosar Ave, Vakilabad Blv., Mashhad, Iran. Tel: +98511-8416694; Mobile: 09151115860; Fax: +98511-8817385; E mail: majidmirsadraee@yahoo.com; m-mirsadraee@mums.ac.ir

© 2013 *mums.ac.ir* All rights reserved.

This is an Open Access article distributed under the terms of the Creative Commons Attribution License (<http://creativecommons.org/licenses/by/3.0>), which permits unrestricted use, distribution, and reproduction in any medium, provided the original work is properly cited.

or bypass the hepatic sinusoids. However they can also reach and trapped to the pulmonary arterial capillary and slowly grow whilst the patient is asymptomatic (primary lung hydatidosis)(2).

Chest radiograph (CXR) is the first line in the diagnosis of pulmonary involvement. Classical radiological appearances of hydatid cysts include a well-defined round opacity (cysts), water lily (meniscus) sign, and so on(3). However, complicated cases may not be differentiable from other conditions such as malignant or infiltrative lung lesions. In these cases, further investigation by means of thoracic CT and bronchoscopy can aid in the diagnosis of this disease. In addition, some lung hydatidosis cases have unusual presentations and can only be identified following surgery and histological examinations (4, 5). Recognition of atypical radiological appearances of pulmonary hydatidosis is very important, especially in endemic areas where the radiologist should always have a high level of suspicion.

The aim of this study was to perform a retrospective study of radiological presentations of pulmonary hydatidosis in a large cohort of cases that presented in a tertiary pulmonary centre in an endemic area.

Materials and Methods

All patients with surgically confirmed pulmonary hydatidosis over a 26-year period were identified. Then we obtained the following data's: patient's records including demographic data (gender, age, occupation, and place of residence) and relevant clinical findings (cough, dyspnea, fever, hemoptysis, and expectoration of phlegm or salty water). Standard CXR was performed in all patients, but the computed tomography scan (CT scan) was done only in those who consented to the examination and could not be diagnosed by other means.

A cross-sectional radiologist reviewed all the images and findings were classified into two sub-categories: typical and atypical radiological findings. Typical radiological findings of lung hydatid cysts included well-defined intact cysts, meniscus signs (crescent signs) and water lily signs. Atypical radiological signs were based on CT scan findings in those patients that revealed radiological findings that were atypical for lung

hydatidosis. These findings include thick wall cavities, lung consolidation including well- or ill-defined heterogeneous densities mimicking round pneumonia, abscesses (air fluid level without a water lily sign), solid looking masses, lesions mimicking a fungal ball, and segmental or lobar lung collapse (atelectasis). The Research Ethical Committee of the Islamic Azad University - Mashhad, Iran, approved this study. Descriptive analysis of the data was performed to calculate frequencies, means, and standard deviations (SD). Variables such as size and diameter of the cysts were compared within two groups (typical and atypical hydatid cyst groups) by using the unpaired two-tailed t-test. The location of the cysts (apical, peripheral and central) were compared in the two groups using the chi-square and odd ratios, and 95% confidence intervals were calculated. A p-value (p) of less than 0.05 was defined as significant.

Results

Over a 26-year period, 1024 patients with pulmonary hydatidosis were diagnosed and operated on. The principal radiological investigation was performed by CXR in all patients. Seventy-nine patients had a thoracic CT scan in which lung and mediastinal windows were reviewed. Mean age (\pm SD) was 29.8 ± 16.1 years (range 5-85 years). Fifty-four percent of the patients were male. Age difference between the genders was not significant (male= 39 ± 20.8 years, female= 41 ± 24 years; student t-test: $t=0.41$, $P=0.68$). Smoking was noted in 116 patients (14%). Sixty-nine percent of patients lived in rural areas. Ten cases (1%) were asymptomatic and were diagnosed incidentally by a routine CXR. In symptomatic patients (1014 subjects), the most frequent complaint was cough in 579 (56.5%), followed by chest pain in 353 (34.5%) patients. Hemoptysis was reported in 305 patients (29.8%), of which 25 were massive. There was a history of previous operations for hydatid disease in 17 patients (1.7%) and a history of trauma in four (0.4%). Clinical findings were compared between typical and atypical cysts diagnosed by a CT scan (Table 1). None of the clinical and demographic findings were significantly more frequent in patients with typical or atypical radiological findings. From 1024 patients, the chest X-rays of 192 patients

Table 1. Comparison of clinical findings in subjects with hydatid cyst diagnosed by CT scan.

	Total	Typical	Atypical	Statistics	P value
Age (years)	40.5 \pm 22.4	41.2 \pm 21.8	39.5 \pm 23.6	T=0.32	NS
Smoking	11(14%)	6 (13%)	5 (16%)	X ² = 0.13	NS
Asymptomatic	5(7%)	4 (80%)	1 (20%)	Fisher=0.31	NS
Cough	68(87%)	39 (57%)	29 (43%)	X ² = 0.44	NS
Fever	54(75%)	34 (63%)	20 (37%)	X ² = 0.31	NS
Hemoptysis	40(53%)	23 (57%)	17 (43%)	X ² = 0.32	NS
Chest pain	43 (56%)	25 (56%)	19 (44%)	X ² = 0.02	NS

Table 2. Frequency of three kind of involvement of hydatid cyst in different lobes of lung detected by chest X ray.

	Intact cyst (540)	Perforated cyst* (179)	Other type of cyst** (113)
Upper lobes	135	44	31
Lower lobes	274	99	59
Right middle lobe or lingula	62	21	13
Two lobes	61	15	8
Three lobes	8	0	2

*perforated cyst includes water lily sign and meniscus sign

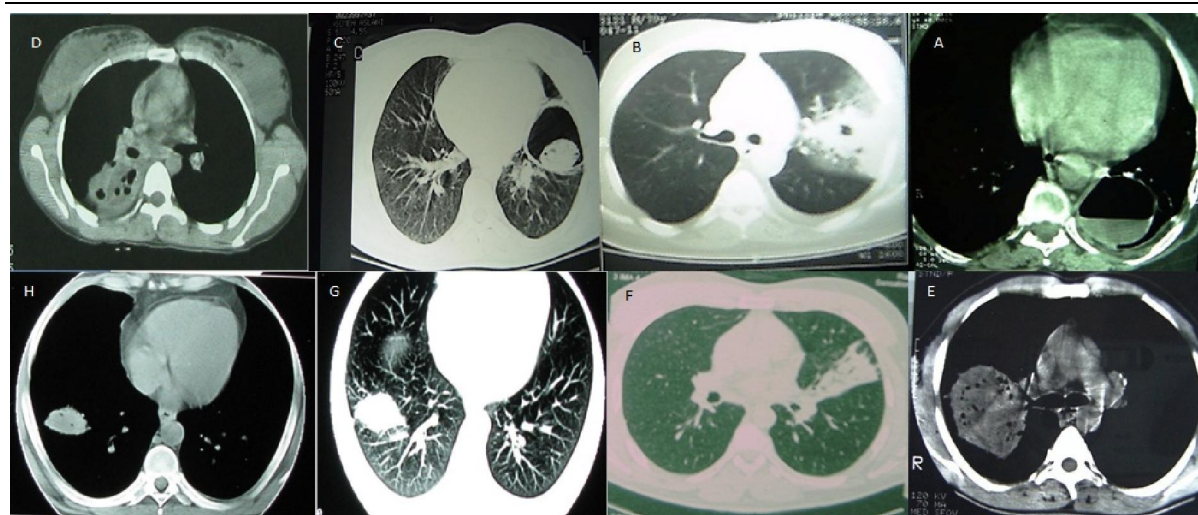
** Other types of cyst includes abscess like lesion, mass like lesion, collapse

could not be interpreted due to indistinctive opacity or obstruction of the view by the heart. From the 832 remaining patients, 540 (64.5%) showed an intact cyst in their chest radiograph. Two hundred ninety two (35.5%) of the remaining patients presented with other radiological findings such as ruptured cysts in 190/292 (65%) cases, abscesses like cysts in 35/292 (11%) cases, alveolar-type infiltration in 15/292 (5%) cases, mass-like density in 12/292 (4%) cases, lobar or segmental collapse in 10/292 (3%) cases and lymphadenopathy in one case (0.3%). Twenty-nine patients (10%) had a combination of the above findings. The lower lobe was the most frequently involved lobe in chest X rays (Table 2), but involvement of up to three lobes was noted. Upper or lower localization was not significantly correlated with a presentation of cysts as intact cysts or complicated cysts ($X^2=0.03$, $P= 0.86$). Seventy-four percent of cysts (757 patients) were localized in the peripheral part of the lung. Cysts

were unilateral in 943 (92.4%) patients (53.6% right-sided and 39.7% left-sided), and bilateral in 68 patients (6.7%) (Table 2). CT scan results were available in 79 patients. Atypical findings were detected in 32 patients (40.5%). From the 47 patients (59.5%) with typical radiological presentations, 43 (91%) had an intact cyst, one (2%) had a crescent sign, and three (7%) had a water lily sign. Seventy percent of all patients showed one cyst; the remaining patients had 2-6 cysts (average 1.7 ± 2.01 cysts in all patients). Number of cysts was not significantly different between typical and atypical cysts (Table 3). In nine patients (28%) who had a CT scan done, the most frequent atypical radiological finding was a thick wall cavity (Figure 1-B). Other findings were as follows: a solid mass in seven (21%) (Figure 1-G), abscess in six (18%) (Figure 1-A), consolidation in three (9%) (Figure 1-D), fungus ball like lesion in three (9%) (Figure 1-C), lung collapse (atelectasis) in two (6%) (Figure 1-F) and round pneumonia in two (6%) (Figure 1-E).

Table 3. Radiological findings in patients with hydatid cyst and comparison of the radiological findings with diameter of cyst.

	Total	Atypical	Typical	Statistics	P value
Count of cyst	1.7 ± 2.01 (1-7)	1.74 ± 1.76 (1-6)	1.52 ± 2.16 (1-7)	T=-1.3	NS
Central localization	20 (25%)	8 (40%)	12 (60%)	$X^2=0.002$	NS
Peripheral localization	59 (74%)	24 (41%)	35 (59%)		
Upper localization	26 (32%)	10 (38%)	16 (62%)	$X^2= 0.06$	NS
Lower localization	53 (68%)	22 (41%)	31 (59%)		
Left sided cyst	31 (39%)	8 (25%)	23 (49%)	$X^2= 4.57$ OR= 2.8	0.032
Right sided cyst	48 (61%)	24 (75%)	24 (51%)		
Cyst diameter	10.55 ± 6.12 cm	10.18 ± 6.4 cm	10.62 ± 6.12 cm	T=-0.8	NS

**Figure 1.** Seven type of atypical radiological presentation of hydatid cyst (1-A abscess, 1-B: thick wall cavity, 1-C: fungus ball like lesion, 1-D: consolidation, 1-E: round pneumonia, 1-F: lung collapse (atelectasis) and 1-G: solid mass).

Pleural effusion was seen in one patient (3%) and this was not significantly higher than patients with typical cysts ($X^2=2.09$, $P=0.09$). The mean (\pm SD) diameter of the hydatid cyst was 10.5 cm (6.1) (51%: <9.9 cm; 32%: 10-19.9 cm; 17%: >20 cm). The diameter of the atypical cyst (10.18 ± 6.4 cm) was not significantly different from the typical cyst (Table 2). In CT scans, cysts were unilateral in 74 patients (94%; 61% right-sided and 39% left-sided), and bilateral in five patients (6%). These localizations were not significantly different from chest X-rays ($X^2= 0.41$, $P= 0.52$). Frequency of atypical cysts on the right side was significantly more than typical cysts (Table 3). Within patients with atypical cysts, the frequency of cavity visibility was significantly more in the right lung (90%) (Fisher exact test; p -value=0.001). Location of cysts in each lung (upper vs. lower or central vs. peripheral) was not associated with increased probability of atypical cysts (Table 2). Mass-like opacity was significantly more frequent in lower lung zones (100%) ($X^2= 3.98$, $P= 0.045$). In atypical cases with lung collapse, one patient (3%) showed lobar collapse and one revealed segmental collapse. Mediastinal lymphadenopathy was observed in one case.

Discussion

Chest X-ray is the first step in the diagnosis of hydatid cysts(6). A CT scan of the chest can provide further information in difficult cases and help recognize complications(7). Radiological diagnoses of lung hydatid cysts could be made if typical CXR signs, such as a well-defined intact cyst, water lily sign, or meniscus sign are present (3) However, this study showed that a significant proportion of confirmed lung hydatid cysts might have alternative presentations. Therefore, clinicians should be aware of hydatid lung lesions resembling the atypical imaging features mentioned above. This presentation may make the diagnosis difficult when procedures such as bronchoscopy and finally surgical exploration may be helpful(4, 8).

In our series, seven atypical radiological pictures were studied with the following presentations: thick wall cavity, solid mass, abscess, consolidation, fungus ball, lung collapse (atelectasis) and round pneumonia. Previous studies have also described atypical radiological presentations of lung hydatidosis. Gupta et al(4) Reported four cases of pulmonary hydatid cysts with atypical chest radiographic presentations. Radiological findings included cavity, solid mass and consolidation. Taha(5) reported three atypical cases of pulmonary hydatidosis in upper lobes presenting

as vague opacities. The author recommended considering hydatid cysts as a differential diagnosis for any unexplained localized lung opacity. Gamez et al (9) reported lung consolidation and pleural effusion as rare presentations of hydatid cysts.

Over 35% of patients in our series revealed atypical radiological presentations. The most frequent atypical radiological finding in our series was thick wall cavities. In another similar study of 77 CT scans, the most frequent atypical pulmonary presentation was solid masses in 15 (19%) patients(10). In this series, pleural involvement was observed in 30% of patients, which was significantly more than in our cases. Pleural involvement included pleural effusion, pleural thickening, pneumothorax or hydropneumothorax(9).

Only 32% (26/79) had upper lobe hydatid cysts (Table 2). Similarly, other investigators such as Zahirifard et al. 9, Yalcinkaya et al (11) and Jerray et al (12) reported upper localizations in 28% (34/124), 36% (8/22) and 18.3% (71/286), respectively. This could be explained by a higher blood supply to lower zones². In our series, CT scan also revealed that 25% of all hydatid cysts were located near to the hilum.

Demographic data such as age, smoking and clinical symptoms were evaluated as potential predictors of presentations of atypical cysts. Although coughing was the most frequent presenting symptom, none of the clinical findings were significantly correlated to atypical hydatid cysts.

One may believe that atypical presentations may be due to complications and larger cysts are more likely to complicate the situation, however; statistical analysis showed no significant correlation between atypical presentations and size. This could be explained by a reduction in the size of large cysts following rupture. Right-sided cysts are more complicated than left-sided cysts.

Conclusion

In conclusion, clinicians should consider the possibility of lung hydatidosis in any patient with a localized sign on a CXR and CT scan, especially in endemic areas. Furthermore, the probability of atypical hydatid cysts presentations cannot be predicted by clinical findings, size, and place of lesion.

Acknowledgement

The authors would like to thank vice chancellery of Research of Islamic Azad University, Mashhad Branch for financial support. Mashhad, Iran.

Conflict of interests

The authors have no conflict of interests.

References

1. Keshmiri M, Baharvahdat H, Fattahi SH, Davachi B, Dabiri RH, Baradaran H, et al . A placebo controlled study of albendazole in the treatment of pulmonary echinococcosis. *Eur Respir J* 1999; 14:503-7.
2. Kilani T, El Hammami S. Pulmonary hydatid and other lung parasitic infections. *Curr Opin Pul Med* 2002;8:218-23.
3. Beggs I. The radiology of hydatid disease. *AJR* 1985; 145:639-48.
4. Dheeraj Gupta, Priya N. Agrawal, Ashutosh N. Aggarwal, Bishan D. Radotra, Digamber Behera, Surinder K. Jindal. Bronchoscopic Diagnosis of Pulmonary Hydatidosis in Patients With Unusual Roentgenologic Appearance. *J Bronchology Interv Pulmonol* 2001;8:101-3.
5. Taha AS. Diagnosis of ruptured pulmonary hydatid cyst by means of flexible fiberoptic bronchoscopy: A report of three cases. *J Thorac Cardiovasc Surg* 2005;130:1196-7.
6. Ramos G, Orduña A, García-Yuste M. Hydatid cyst of the lung: diagnosis and treatment. *World J Surg* 2001;25:46-57.
7. von Sinner W. Advanced medical imaging and treatment of human cystic echinococcosis. *Semin Roentgenol* 1997;32:276-90.
8. Hagh Z, Mirsadraee M, Bagheri R. Bronchoscopic Findings in Patients With Hydatid Cyst of the Lung: Does it Correlate With Radiologic Findings?. *J Bronchology Interv Pulmonol* 2006;13:128-31.
9. Gámez BJ, Cabrera LM, Povedano AC, Kindelan AA, Algar J, et al. Intrabronchial Tumor: An Atypical Presentation of a Hydatid Cyst. *J Bronchol* 2003;10:192-4.
10. Zahirifard S, Kaynama K, Farzanegan R, Tahbaz MO, Abbasi A. Imaging in 100 patients of thoracic hydatid disease including unusual imaging appearance. *Iran J Radiol* 2006;3:91-7.
11. Yalçinkaya I, Er M, Ozbay B, Uğraş S. surgical treatment of hydatid cyst of lung: review of 30 cases. *Eur Respir J* 1999;13:441-4.
12. Jerray M, Benzarti M, Garrouche A, Klabi N, Hayouni A. Hydatid disease of the lung. study of 386 cases. *Am Rev Respir Dis* 1992;146:185-9.