

Tricuspid Valve Endocarditis in an Intravenous Drug Abuser: A Case Report

Hamid Hoseinikhah, Aliasghar Moeinipour*

Cardiac Surgeon, Department of Cardiac Surgery, Imam Reza Hospital, Mashhad University of Medical Sciences, Mashhad, Iran

ARTICLE INFO

Article type:
Case report

Article history:
Received: 15 Jan 2015
Revised: 20 March 2015
Accepted: 30 March 2015

Keywords:
Infective Endocarditis
Intravenous Drug Abuser
Tricuspid Valve

ABSTRACT

Recently, there have been more reports of cardiac valve infections due to the increasing number of intravenous (IV) drug abusers and chronic renal failure patients. Among cardiac valves, tricuspid valve is most commonly affected in the course of endocarditis.

Appropriate management of these patients is a challenging and controversial issue in the field of cardiac surgery. Treatment options in such cases include IV antibiotics, surgical excision alone, and surgical excision with the re-implantation of prosthetic valve.

In this study, we present a case of tricuspid valve endocarditis (TVE), confirmed by echocardiography, in a young IV drug abuser. Tricuspid valve replacement was performed by using a biological prosthesis with remarkable results in the early and long-term follow-up of the patient.

► Please cite this paper as:

Hoseinikhah H, Moeinipour A. Tricuspid Valve Endocarditis in an Intravenous Drug Abuser: A Case Report. J Cardiothorac Med. 2015; 3(2):316-318.

Introduction

Within the past two decades, there have been more reports of cardiac valve infections, especially due to the increasing number of intravenous (IV) drug abusers. In addition, patients with chronic indwelling catheter for hemodialysis and chemotherapy and those with permanent endocardial pacing lead are most susceptible to this type of infection. In cases of cardiac valve endocarditis in IV drug abusers, the tricuspid valve is most commonly affected, resulting in tricuspid valve regurgitation (1).

The presentations of tricuspid valve endocarditis (TVE) include fever, symptoms of right-sided heart failure, peripheral edema, hepatomegaly, and ascites. The diagnosis of TVE is normally confirmed by transthoracic and transesophageal echocardiography. Most cases of Tricuspid Valve Endocarditis are young patients with long history of I.V drug abusers. In case of tricuspid valve endocarditis, indications for surgical intervention consist of vegetation larger than 10 mm, persistent sepsis despite 6 weeks of

appropriate IV antibiotic therapy, presence of signs and symptoms of right-sided heart failure, and recurrent embolic episodes. The initial treatment involves administration of IV antibiotics based on blood culture sampling (2, 3).

Despite various treatment options for the management of TVE, such as surgical interventions, the optimal treatment is still debatable (4, 5).

Case Report

A 24-year-old man with a history of IV drug abuse and positive for hepatitis C was referred to our hospital for further examinations. In the physical examination of the patient, he showed signs and symptoms of right-sided heart failure, especially with edema on the extremities without ascites. According to the transthoracic echocardiography examination of the patient, the tricuspid valve was affected by infective endocarditis with signs of severe valvular regurgitation. In addition, a large vegetation

*Corresponding author: Aliasghar Moeinipour, Department of Cardiothoracic Surgery, Imam Reza Hospital, Mashhad University of Medical Sciences, Mashhad, Iran. Tel: +9851-38525307; Fax: +9851-380223; E-mail: Moeinipoura@mums.ac.ir

© 2015 mums.ac.ir All rights reserved.

This is an Open Access article distributed under the terms of the Creative Commons Attribution License (<http://creativecommons.org/licenses/by/3.0>), which permits unrestricted use, distribution, and reproduction in any medium, provided the original work is properly cited.

(about 2 cm) was observed on the anterior leaflet of the tricuspid valve (Figure 1).

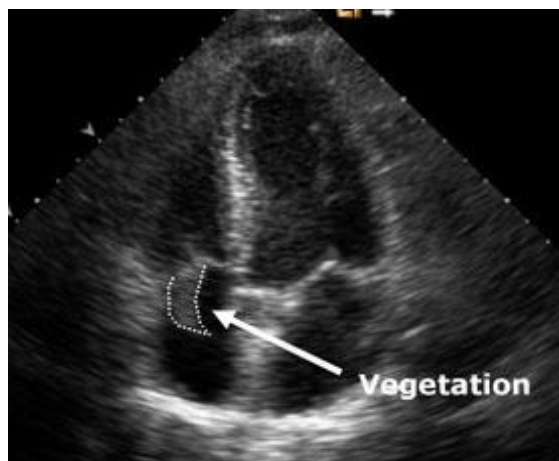


Figure 1. Large mobile vegetation on Tricuspid Valve

Other cardiac valves were intact. Upon obtaining the essential sampling, empiric antibiotics containing Imipenem and Vancomycin were initiated and the patient was scheduled for surgery. After median sternotomy and Heparin administration with aortic and bicaval cannulation, cardiopulmonary bypass (CPB) was initiated.

Upon opening the right atrium while inspecting the tricuspid valve, we observed severe malcoaptation of the tricuspid leaflet with leaflet perforation and large vegetation on the anterior mitral leaflet. The intra-operative examination of this valve by saline test was indicative of severe regurgitation.

Following the excision of the infected valve, which had been sent for pathological examinations, tricuspid valve replacement was performed by number-31 biological prosthesis. After closing the right atrium, the patient was weaned from cardiopulmonary bypass machine.

According to the patient's follow-up, he remained in a desirable condition. Moreover, the serial echocardiographic examination of the prosthetic valve was indicative of a good hemodynamic status. In addition, no paravalvular leaks (PVL) or signs of recurrent infections were detected.

Antibiotic therapy continued for 6 weeks and the patient was discharged 10 days after the surgery. Overall, the patient has been afebrile and in good clinical condition ever since.

Discussion

The etiology of TVE has recently changed due to the increasing number of IV drug abusers, more frequent usage of intravenous catheters for chronic renal replacement therapy and chemotherapeutic agents (4, 5).

The optimal management of TVE is still a controversial issue. According to the literature, there are certain indications for surgical intervention including: persistent or recurrent infection despite appropriate antibiotic therapy, right-sided heart failure, and large mobile vegetation. The surgical intervention could involve valve excision only or tricuspid valve replacement (6-8).

Each of the proposed strategies in this regard has particular advantages, as well as certain shortcomings. Some surgeons have recently trialed to repair the tricuspid valve in selected cases of TVE. Nowadays, valve excision is not advocated by many medical experts, since surgical valve excision alone without replacing the valve could not be easily tolerated by many patients causing severe right-sided heart failure and the probable need for future surgery (8).

Although the gold standard procedure for TVE is tricuspid valve replacement, this procedure requires lifelong anticoagulation therapy. Moreover, it involves the risk of recurrent infections of the prosthetic valve. For this reason, some surgeons have recently used tricuspid valve repair method in cases of TVE. However, it should be pointed out that the repair technique could be only used in the selected cases of TVE (8-10).

Drug avoidance after surgery in addict patients is the key to the successful management of TVE. Overall, the patient prognosis, either by tricuspid valve repair or tricuspid valve replacement, is a viable option with a low risk of recurrent infections, especially in non-intravenous drug users.

Conclusion

Tricuspid Valve Replacement for tricuspid valve endocarditis in I.V drug Abusers is a safe procedure with good outcome.

Conflict of Interests

The authors declare no conflict of interest.

References

1. Mylonakis E, Calderwood SB. Infective endocarditis in adults. *N Engl J Med.* 2001; 345:1318-3
2. Chan P, Ogilby JD, Segal B. Tricuspid Valve Endocarditis. *Am Heart J.* 1989; 117:1140-6.
3. Bouza E, Menasalvas A, Munoz P, Vasallo FJ, del Mar Moreno M, García Fernández MA. Infective endocarditis: A prospective study at the end of the twentieth century – new predisposing conditions, new etiologic agents and still a high mortality. *Medicine (Baltimore).* 2001;80:298-307
4. Yee ES, Ulliyot DJ. Reperative approach for right side endocarditis. *Operative*

- consideration and result of Valvoplasty. *J Thorac Cardiovasc Surg.* 1988;96:133-40.
5. Jagger JD, Mccaughan BC, Pawsey CGK. Tricuspid valve Endocarditis cure by excision of a single vegetation. *Am Heart J* 1986; 112: 626-7.
 6. Dreyfus G, Serraf A, Jebera VA. Valve repair in acute endocarditis. *Ann Thorac surg.* 1990;49:706-13.
 7. Winston LG, Bolger AF. Modern epidemiology, prophylaxis, and diagnosis and therapy for infective endocarditis. *Curr Cardiol Rep.* 2006;8:102-8.
 8. Sande MA, Lee BL, Millills J, Chambers HF. Endocarditis in intravenous drug users. In: Kaye D, editor. *Infective endocarditis.* 2nd ed. New York: Raven Press; 1992. pp. 345-59.
 9. Moreillon P, Que Y-A. Infective endocarditis. *The Lancet.* 2004; 363:139-49.
 10. Cooper H, Brady J, Ciccarone D, Tempalski B, Gostnell K, Friedman SR. Nationwide increase in the number of hospitalizations for illicit injection drug use-related infective endocarditis. *Clin Infect Dis.* 2007; 45:1200-3.