

## Right Atrium Laceration with Pericardial Tamponade: A Rare Presentation of Blunt Cardiac Trauma

Hamid Hoseinikhah<sup>1</sup>, Behzad Alizadeh<sup>2</sup>, Alireza Sepehri Shamloo<sup>3</sup>, Narges Imani<sup>4</sup>, Asadollah Sharifian<sup>5</sup>, Aliasghar Moeinipour<sup>6\*</sup>

<sup>1</sup> Cardiac Surgeon, Cardiac Surgery Department of Cardiac Surgery, Atherosclerosis Prevention Research Center, Imam Reza Hospital, Faculty of Medicine, Mashhad University of Medical Sciences, Mashhad, Iran

<sup>2</sup> Pediatric cardiologist, Imam Reza Hospital, Faculty of Medicine, Mashhad University of Medical Sciences, Mashhad, Iran

<sup>3</sup> Medical Student, Student Research Committee, Mashhad University of Medical Sciences, Mashhad, Iran

<sup>4</sup> Nursing of Cardiac Operation Room, Imam Reza Hospital, Faculty of Medicine, Mashhad University of Medical Sciences, Mashhad, Iran

<sup>5</sup> Head Nursing of Cardiac Operation Room, Imam Reza Hospital, Faculty of Medicine, Mashhad University of Medical Sciences, Mashhad, Iran

<sup>6</sup> Cardiac Surgeon, Atherosclerosis Prevention Research Imam Reza Hospital, Faculty of Medicine, Mashhad University of Medical Sciences, Mashhad, Iran

### ARTICLE INFO

Article type:  
Case Report

Article history:  
Received: 15 Jun 2015  
Revised: 20 Aug 2015  
Accepted: 15 Oct 2015

Keywords:  
Cardiac Trauma  
Laceration  
Tamponade

### ABSTRACT

Cardiac laceration from blunt thoracic trauma is not a common presentation. The rate of mortality due to this injury is very high since it is not diagnosed and treated immediately. In this study, we present the case of a 65-year-old man with blunt cardiac trauma, causing right atrial rupture and pericardial tamponade. Successful management of this patient was firstly done with initial pericardiocentesis. Then, the patient was immediately transferred to the operating room for tamponade relief and cardiac wall repair. We recommend that cardiac surgeon have an important suspicious for cardiac involvement in Blunt chest wall trauma.

► Please cite this paper as:

Hoseinikhah H, Alizadeh B, Sepehri Shamloo A, Imani N, Sharifian A, Moinipour A. Right Atrium Laceration with Pericardial Tamponade: A Rare Presentation of Blunt Cardiac Trauma. *J Cardiothorac Med.* 2015; 3(4):384-386.

### Introduction

The majority of cardiac traumas associated with laceration are caused by penetrating trauma. Cardiac laceration from penetrating trauma is usually in the right ventricle (1-3). Cardiac trauma in blunt thoracic injuries is a common presentation; however, incidence of cardiac contusion and laceration from blunt cardiac trauma is highly uncommon. Cardiac blunt trauma can occur in motor vehicle crashes and falling injuries (1).

Multiple rib fractures (especially in rib numbers 4, 5 and 6) are distinctive signs of cardiac blunt trauma (4).

The majority of patients with pure cardiac trauma have hemodynamic stability; therefore, any hemodynamic deterioration can be due to cardiac tamponade. The most common pattern of blunt cardiac trauma is cardiac contusion (5). Occasionally, CX-ray criteria for tamponade diagnosis are ostensible.

Despite the above mentioned examinations can help with the diagnosis of blunt cardiac trauma, the gold standard for confirmation of cardiac injury is echocardiography, which can be promptly used in emergency department (6, 7). Although in laboratory data of cardiac trauma, troponine and creatine phosphokinase are

\*Corresponding author: Aliasghar Moeinipour, Atherosclerosis Prevention Research Imam Reza Hospital, Faculty of Medicine, Mashhad University of Medical Sciences, Mashhad, Iran. Tel/Fax: +985138022312; E-mail: moeinipooral@mums.ac.ir

© 2015 *mums.ac.ir* All rights reserved.

This is an Open Access article distributed under the terms of the Creative Commons Attribution License (<http://creativecommons.org/licenses/by/3.0>), which permits unrestricted use, distribution, and reproduction in any medium, provided the original work is properly cited.

elevated, these signs are not specific to this condition.

In cases of cardiac contusion, the most effective treatment is conservative therapy with close monitoring of patients in Intensive Care Unit, as well as examining the multiple trauma patients for other possible organ injuries. The course of recovery in most patients is uneventful and patients are discharged in a good clinical condition.

Cardiac laceration from blunt cardiac trauma is very uncommon in thoracic trauma patients (2).

In cases with cardiac tamponade from cardiac laceration, patients are almost hypertensive with signs of acute cardiac failure, distended jugular venous pressure (JVP) and dyspnea. In emergency departments, pericardial space can be evacuated in unstable patients with pericardiocentesis for temporary release of cardiac failure and safe transfer of patients to operating rooms.

In most cases, the treatment procedure for traumatic cardiac tamponade is median sternotomy; after opening the pericardium, massive clots are removed and the site of hemorrhage is controlled.

### Case presentation

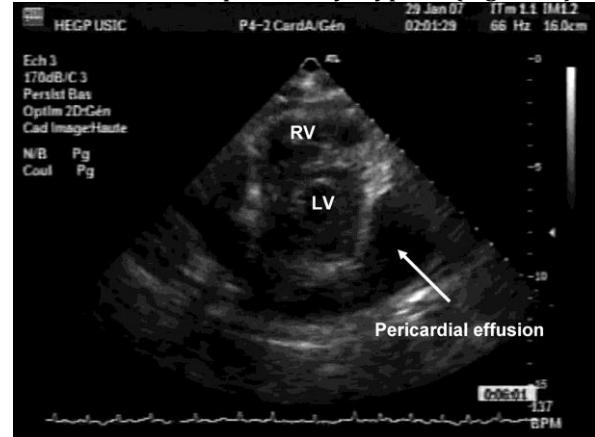
We present the case of a 65-year-old man with multiple trauma from a car accident (he had not fastened seat belt). The patient at arrival to the emergency department was in respiratory distress and hypotensive in hemodynamic evaluation (blood pressure=70/50). In his examination, the heart sound was not heard clearly, and in the standard work-up, distended JVP was observed. He did not have any significant problems in other systems. In chest x ray Fracture rib between 3 to 6 ribs was seen. Cradiothoracic ratio was in normal range and without hemothorax. Preoperative laboratory examination had not any significant problem.

After resuscitation of the patient with suspected cardiac injury and tamponade, echocardiography examination was done in the emergency department. The results demonstrated cardiac tamponade with significant pericardial fluid circumference; moreover, the patient met the echocardiographic criteria for cardiac tamponade (Figure 1).

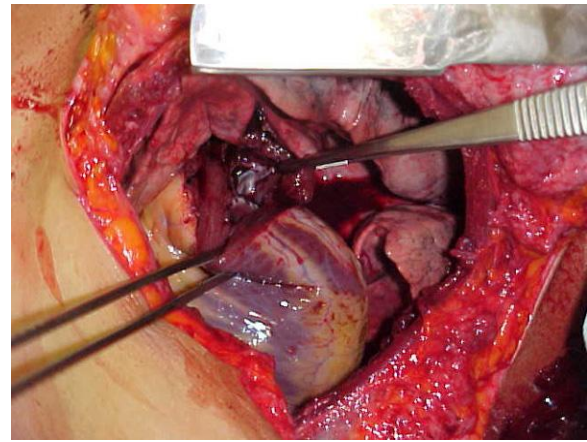
Due to instability of hemodynamic status, decompression of pericardial space with pericardiocentesis was performed, which successfully removed about 50 cc bloody liquid. The patient was rapidly transferred to the operating room.

Through median sternotomy, massive clots were removed from the pericardium. Fresh

bleeding was noticed from the right atrium, which was repaired with prolen suture without the use of cardiopulmonary bypass (Figure 2).



**Figure 1.** Echocardiographic findings of pericardial tamponade in blunt cardiac trauma



**Figure 2.** Right atrial laceration arising from the blunt trauma

The patient's postoperative course was uneventful and he was discharged six days following the surgery in a good clinical status.

### Discussion

The majority of cases with cardiac laceration are caused by thoracic traumas such as stab wound and gunshot (1). Cardiac wall laceration from blunt trauma is a highly uncommon presentation (5).

A significant percentage of patients with cardiac laceration, especially from penetrating injury, die before hospital admission or any medical interventions (4, 5). Overall, blunt cardiac injury can vary from completely asymptomatic cardiac contusions to cardiac wall lacerations with pericardial tamponade and high mortality (7).

The most common causes of this trauma are motor vehicle accidents and falling traumas, respectively (8). Blunt thoracic trauma with cardiac injury includes cardiac contusion and cardiac wall rupture. Other possible rare complications from blunt trauma consist of

ventricular septal rupture, tricuspid valve rupture and coronary arteriovenous fistula formation, all of which can be presented either immediately or later after traumatic injury (9-11). The most common types of cardiac traumas are cardiac contusion and cardiac wall rupture.

The first cardiac wall laceration report was presented by Suszoko in 1968. The most common sites of cardiac rupture from blunt trauma are the right ventricle and the right atrium due to their anatomical positions (compressed between sternum and vertebral column) (12). As compared to cardiac laceration, blunt thoracic trauma can lead to acute dysfunction of tricuspid and mitral valve from rupture of papillary muscle and chorda. All of this involvement can lead to severe valvular regurgitation. Patients with these complications present with acute heart failure (12).

Given the fact that cardiac wall laceration arising from blunt thoracic trauma is not a common finding, it is not immediately diagnosed; moreover, emergent surgical interventions are not usually performed, leading to poor prognosis of patients.

Accurate diagnosis of this injury requires high clinical suspicion in victims of traumatic accidents. Cardiac wall laceration should be suspected in all traumatic patients, especially if the patient has sternum fracture, as well as anterior rib fracture between ribs number 3 and 6.

In patients presenting with signs of increased central venous pressure and concomitant hypotension, without a clear heart sound, cardiac laceration and pericardial tamponade should be suspected.

## Conflict of Interest

The authors declare no conflict of interest.

## References

1. Kang N, Hsee L, Rizoli S, Alison P. Penetrating cardiac injury: overcoming the limits set by Nature. *Injury*. 2009; 40:919-27
2. Marshall DT. The spectrum of findings in cases of sudden death due to blunt cardiac trauma--commotio cordis. *Am J Forensic Med Pathol*. 2008; 29:1-4.
3. Farhataziz N, Landay M. Pericardial rupture after blunt chest trauma. *J Thorac Imaging*. 2005; 20:50-2.
4. Ismailov RM, Weiss HB, Ness RB, Lawrence BA, Miller TR. Blunt cardiac injury associated with cardiac valve insufficiency: trauma links to chronic disease? *Injury*. 2005; 36:1022-8.
5. Schultz JM, Trunkey DD. Blunt cardiac injury. *Crit Care Clin*. 2004; 20:57-70.
6. Kutsukata N, Sakamoto Y, Mashiko K, Ochi M. Morphological evaluation of areas of damage in blunt cardiac injury and investigation of traffic accident research. *Gen Thorac Cardiovasc Surg*. 2012; 60:31-5.
7. Kato K, Kushimoto S, Mashiko K, Henmi H, Yamamoto Y, Otsuka T. Blunt traumatic rupture of the heart: An experience in Tokyo. *J Trauma*. 1994; 36:859-63.
8. Bansal MK, Maraj S, Chewaproug D, Amanullah A. Myocardial contusion injury: redefining the diagnostic algorithm. *Emerg Med J*. 2005; 22:465-9.
9. Katyal D, McLellan BA, Brenneman FD, Boulanger BR, Sharkey PW, Waddell JP. Lateral impact motor vehicle collisions: significant cause of blunt traumatic rupture of the thoracic aorta. *J Trauma*. 1997; 42:769-72.
10. Elie MC. Blunt cardiac injury. *Mt Sinai J Med*. 2006; 73:542-52.
11. Susozko B. Heart injury caused by a rib fragment. *Pol Tyg Lek*. 1968; 23:595.