

## Urgent Surgical Intervention for Embolized Cardiac Occluder Devices: A Case Series

Ashish Avinash Baviskar, Chandan Kumar Ray Mohapatra, Chaitanya Raut, Jayant Khandekar

Department of Cardiovascular and Thoracic Surgery, Lokmanya Tilak Municipal Medical College and Sion Hospital, Mumbai, India

### ARTICLE INFO

*Article type:*  
Case Series

*Article history:*  
Received: 27 Apr 2017  
Revised: 11 May 2017  
Accepted: 20 May 2017

*Keywords:*  
Atrial Septal Defect  
Embolize  
Occluder Device  
Ventricular Septal Defect

### ABSTRACT

**Introduction:** In this study, we sought to illustrate our experience in urgent surgical management for embolized cardiac septal occluder devices resulting from trans-catheter closure of atrial septal defect and ventricular septal defect.

**Materials and Methods:** We retrospectively reviewed four patients aged 2–10 years who underwent urgent surgery due to cardiac septal occluder embolization between December 2015 and December 2016. Congenital defects were atrial septal defect (n=2) and ventricular septal defect (VSD) (n=2). Risk factors for device embolization and the need for urgent surgical retrieval/definitive management techniques for embolized device removal are discussed.

**Results:** Removal of embolized devices was performed in all the cases. Inevitably, in three patients the primary defect was closed, while in one case of VSD the device was removed without closing the defect. All the operations were completed successfully and no hospital mortality or morbidity was encountered.

**Conclusions:** Although closure of left to right shunting defects by percutaneous occluder devices has several advantages, device embolization is still a major complication. If embolized device retrieval fails with percutaneous intervention attempts, surgical management is the only method to remove embolized devices. In this circumstance, to provide an uneventful perioperative course, urgent management strategies should be well planned.

► Please cite this paper as:

Baviskar AA, Ray Mohapatra CHK, Raut Ch, Khandekar J. Urgent Surgical Intervention for Embolized Cardiac Occluder Devices: A Case Series. *J Cardiothorac Med.* 2017; 5(2): 575-578.

## Introduction

Congenital heart diseases such as atrial septal defect (ASD) and ventricular septal defect (VSD) are common types of pediatric cardiac diseases. Before the first description of the transcatheter closure of ASD by King et al., the surgical repair was the treatment of choice for all such defects (1). The percutaneous transcatheter closure of septal defects has recently become an increasingly widespread alternative to surgical closure in many centers. However, these interventional procedures are accompanied with major complications such as device embolization. The management of the

embolized device has been discussed in the surgical literature. These studies suggest that embolized devices have a tendency to migrate to the right side of the heart, mainly to pulmonary artery (2). Herein, we presented four cases of attempted percutaneous transcatheter closure, complicated by device embolization necessitating emergency surgical retrieval.

## Case Presentation

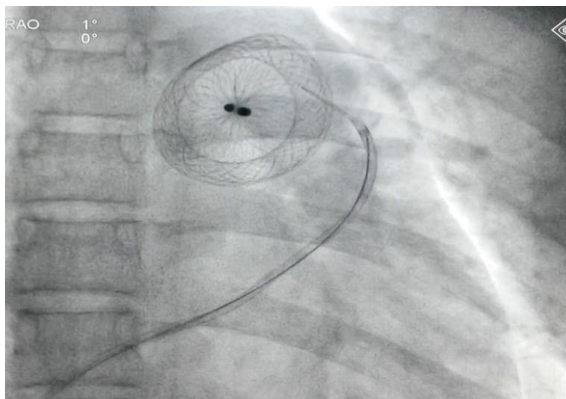
### Case 1

An asymptomatic 16-year-old male with

\*Corresponding author: Ashish Avinash Baviskar, Department of Cardiovascular and Thoracic Surgery, Lokmanya Tilak Municipal Medical College and Sion Hospital, Maharashtra, India. Tel: 919820869767; Email: ash22kar@gmail.com

© 2017 *mums.ac.ir* All rights reserved.

This is an Open Access article distributed under the terms of the Creative Commons Attribution License (<http://creativecommons.org/licenses/by/3.0>), which permits unrestricted use, distribution, and reproduction in any medium, provided the original work is properly cited.



**Figure 1.** Embolization of Amplatzer atrial septum defect occluder device into the main pulmonary artery

ostium secundum (OS) ASD measuring 22 mm on the transthoracic echocardiography (TEE) was underwent transcatheter closure with a 30 mm Amplatzer device. The procedure was failed due to dislodgment of the device into MPA (Figure 1). The retrieval of the dislodged device was attempted, but faced with failure since the guidewire got entangled into the chords of the tricuspid valve. Due to hemodynamically instability, emergency surgical intervention was advised to retrieve the device.

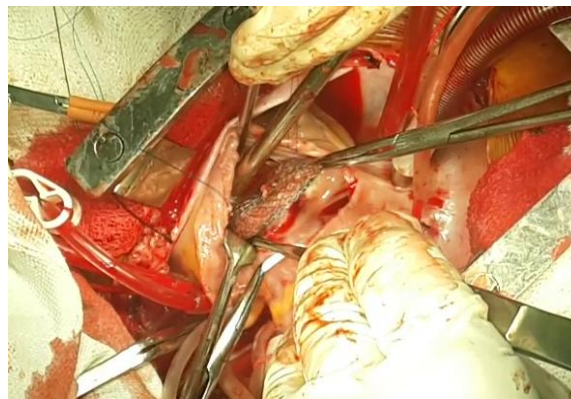
On surgery, a large secundum ASD (30×40 mm) was found with no tissue “shelf” at the inferior margin. The device was covered with fresh thrombus and embolized entirely into the main pulmonary artery. It was retrieved without injury to main pulmonary artery, and entangled part of the guidewire was removed through femoral route. Subsequently, the ASD closed with an autologous pericardial patch. The patient had an uneventful recovery and discharged a week later. He remained well during the four-month follow-up.

#### Case 2

A 48-year-old male with OS-ASD measuring 24 mm on TEE with adequate rims was taken for device closure. The transcatheter closure was attempted; however, the device closure failed and dislodged into the right ventricular outflow tract. The patient became hemodynamically unstable, shifted to the operation theatre. On operation, the right atrium opened longitudinally, and the Amplatzer device was retrieved from the right ventricular outflow tract (Figure 2). Subsequently, the ostium secundum ASD (25×15 mm) was closed with fresh autologous pericardial patch. The patient had an uneventful recovery and was discharged a week later. He remained well during the one-year follow-up.

#### Case 3

An 18-month-old female infant with perimem-

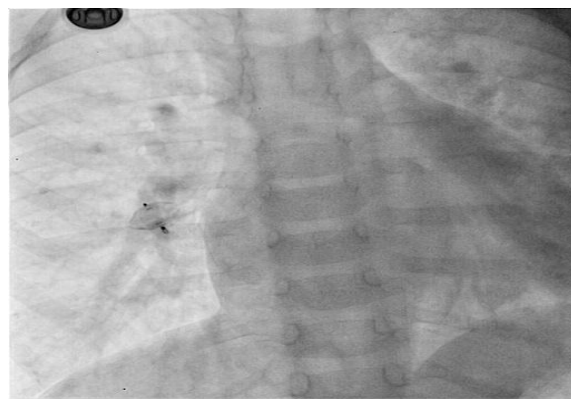


**Figure 2.** Removal of Amplatzer device from the right ventricular outflow tract

branous and subaortic restrictive VSD (4 mm) with left to right shunt on the TTE was underwent for transcatheter closure. The transcatheter closure was performed under fluoroscopic control. As the device deployed, it embolized into the right pulmonary artery (Figure 3). The patient was shifted to the operation room, and the median sternotomy was performed. The right pulmonary artery was dissected till lobar branches, no device felt externally by the finger. When the right pulmonary artery was opened, the device was visualized intraluminally at the lobar branch of the middle lobe. It was retrieved gently from the right pulmonary artery. Afterwards, the VSD was closed using PTFE felt patch. The patient recovered without any postoperative complications and was discharged a week later. She was well after the six-month follow-up.

#### Case 4

A five-year-old asymptomatic female patient with perimembranous VSD (7 mm) with left to right shunt, showing no pulmonary arterial hypertension on the TTE was taken for device closure in the cathlab. The attempted device closure was failed and the device embolized into the descending thoracic aorta below the level of the crossing left renal vein. The patient was



**Figure 3.** Embolized Amplatzer ventricular septal defect occluder device into the right pulmonary artery

thermodynamically stable and shifted to the operation room. Laprotomy was performed, and after mobilizing complete bowel, vertical aortotomy was carried out just below the level of crossing left renal vein. Therefore, the device was retrieved through aortotomy. The patient had an uneventful recovery and was discharged a week later. She was followed up, and the VSD closure was performed surgically after six months without any postoperative complications. She was discharged a week later.

## Discussion

Although the surgical repair of ASD and VSD yields extremely low morbidity and mortality, the interventional transcatheter closure for all types of cardiac defects with left to right shunting gained wide popularity. The recent studies strongly suggest that transcatheter device closure is safe method for both adult and child patients, with shorter hospital stay less mortality and morbidity rates. Moreover, this therapeutic approach obviates surgical risk factors and inevitable surgery scar. None the less, this procedure is not complications free. The reported complications of the transcatheter closure include, device malposition, residual shunt, caval thrombosis, systemic or pulmonary embolization, thromboembolism, erosion and perforation of the heart, and atrial arrhythmia (3, 4). The device embolization may cause serious damage due to embolization at unexpected sites of circulatory system. The reported embolization rates are 4% and 20% in 1991 (5) and 1996 (6), respectively, which dramatically decreased to 0.55% in 2005 (7). Out of the 81 transcatheter closures (i.e., 50, 12, and 19 ASD, VSD, and patent ductus arteriosus, respectively) performed in our institute in the last year (December 2015-December 2016), four cases (i.e., 2 ASD and 2 VSD) needed emergency surgical management due to septal occluder device embolization. All the four devices were embolized within 10 min of deploying the device.

The most common cause of device failure is improper patient or device selection. One of the the major cause of device dislodgement is size of the defect greatly exceeding the waist diameter of the device. On the other hand, erosion and perforation can occur with oversizing of device, especially when there is a defect with a deficient anterosuperior rim. The patients in whom we can not achieve satisfactory device position or significant residual defect is remaining inspite of device closure, device retrieval is usually best option at the time of implantation and subsequent elective surgical closure should be done. However, if embolization (in which transcatheter snaring and retrieval is unsuccessful) occurs, urgent surgical therapy is necessary.

Device removal should be performed mainly through the right atrium depending on the position of the embolized device. Performing right atriotomy provides a good surgical exposure to all intracardiac structures even to the left ventricle via ASD. The intracardiac structure damages at valvular and subvalvular apparatus caused by percutaneous device retrieving attempts should be repaired. Those devices, which embolize to the ascending or descending aorta should be removed via aortotomy after confirming their positions with TEE. Perioperative TEE guidance is essential particularly in these patients since the device migration might occur after aortic cannulation and initiation of cardiopulmonary bypass.

## Conclusion

The device closure for congenital septal defects is less invasive than the surgery; furthermore, this technique obviates the surgical risk factors and the inevitable surgery scar. The device closure failures may be prevented by appropriate patient selection, and also proper selection of the size of the devices. However, embolization is still a major complication in interventional closure of the cardiac defects. In case of the failure of the percutaneous catheter retrieval attempts, surgical management would be the only method to remove the embolized devices. Therefore, the surgeon should be present in place and also be prepared for the removal of the embolized device.

## Informed consent

Written informed consent was obtained from the patient for publication of this Case Report and any accompanying images.

## Disclaimers

None.

## Funding/financial support

This research received no specific grant from any funding agency in the public, commercial or not-for-profit sectors.

## Conflict of Interest

The authors declare no conflict of interest.

## References

1. King TD, Thompson SL, Steiner C, Mills NL Secundum atrial septal defect Nonoperative closure during cardiac catheterization JAMA 1976; 235:2506-9.
2. Sarris GE, Kirvassilis G, Zavaropoulos P, Belli E, Berggren H, Carrel T, et al Surgery for complications of trans-catheter closure of atrial septal defects: a multi-institutional study from the European congenital heart surgeons association Eur J Cardiothorac Surg 2010; 37:1285-90.

3. Knott-Craig CJ, Goldberg SP Emergent surgical retrieval of embolized atrial septal defect closure device *Ann Thorac Surg* 2008; 85:319-21.
4. Agarwal SK, Ghosh PK, Mittal PK Failure of devices used for closure of atrial septal defects: mechanisms and management *J Thorac Cardiovasc Surg* 1996; 112:21-6.
5. Latson LA, Benson LN, Hellenbrand WF, Mullins CE, Lock JF Transcatheter closure of ASD-early results of multicenter trial of the Bard clamshell septal occluder *Circulation* 1991; 84:544.
6. Worms Am, Rey C, Bourlon F, Losay J, Marcon F, Godart F, et al French experience in the closure of atrial septal defects of ostium secundum type with the Sideris button occluder *Arch Mal Coeur Vaiss* 1996; 89:509-15.
7. Tan CA, Levi DS, Moore JW Embolization and transcatheter retrieval of coils and devices *Pediatr Cardiol* 2005; 26:267-74.