

## The Role of Nuclear Medicine in the Diagnosis and Management of Solitary Pulmonary Nodules

Farzaneh Shariati<sup>1</sup>, Toktam Hosseinneshad<sup>1</sup>, Kamran Aryana<sup>1</sup>, Seyed Rasoul Zakavi<sup>1</sup>, Asieh Sadat Fattahi<sup>2</sup>, Donya Farrokh Tehrani<sup>3</sup>, Keyvan Sadri<sup>1</sup>, Ramin Sadeghi<sup>1\*</sup>

<sup>1</sup> Nuclear Medicine Specialist, Nuclear Medicine Research Center, Mashhad University of Medical Sciences, Mashhad, Iran

<sup>2</sup> General Surgeon, Minimally Invasive and Endoscopic Surgery Research Center, Mashhad University of Medical Sciences, Mashhad, Iran

<sup>3</sup> Radiologist, Radiology department, Imam Reza Hospital, Mashhad University of Medical Sciences, Mashhad, Iran

### ARTICLE INFO

*Article type:*  
Review Article

*Article history:*  
Received: 15-March-2013  
Revised: 14-Sep-2013  
Accepted: 18-Sep-2013

*Keywords:*  
FDG  
PET  
Scintigraphy  
Somatostatin Receptor

### ABSTRACT

Solitary pulmonary nodule (SPN) is a frequent finding on the chest x-ray and computed tomography. Nuclear medicine techniques play an important role in the diagnosis and management of SPN. In the current review, we briefly will explain the different nuclear medicine modalities in this regard including positron emission tomography (PET) using 18-F-FDG, and 11-C-Methionine, and single photon emission computerized tomography (SPECT) using somatostatin receptor scintigraphy, 201-Thallium, and 99m-Tc-MIBI.

#### ► Please cite this paper as:

Shariati F, Hosseinneshad T, Aryana K, Zakavi R, Fattahi A, Farrokh Tehrani D, Sadri K, Sadeghi R. The Role of Nuclear Medicine in the Diagnosis and Management of Solitary Pulmonary Nodules. *J Cardiothoracic Med.* 2013;1(3):73-78.

## Introduction

Solitary pulmonary nodule (SPN) is a frequent finding on the chest x-ray and computed tomography (1). SPN is defined as a single pulmonary opacity smaller than 3cm which is surrounded by normal lung tissue and is not associated with underlying pulmonary disease or adenopathy (2).

The major step in diagnosing and management of SPN is to determine whether it is malignant or benign using non-invasive techniques. The non-invasive tools used include: clinical features (age, smoking history, exposure to toxic environment, history of previous tumors or infections such as tuberculosis), CT findings (SPN size, growth rate, location, nodules margins, enhancement, and invasion), positron emission tomography (PET)

and PET/CT and single photon emission computed tomography (SPECT) or SPECT/CT. The advantages of this approach are to avoid unnecessary invasive intervention for diagnosis and treatment of the benign SPN and to proceed to further invasive investigations such as percutaneous or bronchoscopic transbronchial biopsies, thoracoscopy or thoracotomy for SPN with high suspicion of malignancy (3).

Often SPNs are discovered as incidental findings on CXR or CT scan. These modalities can provide information about nodule size, margin characteristics and calcification patterns which can assist in differentiating benign versus malignant lesions (4). Lesions with well circumscribed smooth borders, benign patterns of calcification, less than 2 cm in size and stability over 2 years on follow up CXR or CT are

\*Corresponding author: Ramin Sadeghi, Nuclear Medicine Research Center, Mashhad University of Medical Sciences, Mashhad, Iran, Tel: +985118012202; Fax: +985118933186; Email: [sadeghir@mums.ac.ir](mailto:sadeghir@mums.ac.ir); [raminsadeghi1355@yahoo.com](mailto:raminsadeghi1355@yahoo.com)

© 2013 *mums.ac.ir* All rights reserved.

This is an Open Access article distributed under the terms of the Creative Commons Attribution License (<http://creativecommons.org/licenses/by/3.0>), which permits unrestricted use, distribution, and reproduction in any medium, provided the original work is properly cited.

considered to be benign nodules. Patients with low possibility of malignancy according to medical history, risk factors and nodule characteristics on the above-mentioned modalities, can be followed with serial chest radiographs or CT scans every 3-6 months (5). This approach can decrease the morbidity of more invasive methods and is highly cost effective.

The use of newer imaging modalities, includes conventional nuclear medicine radiotracers using SPECT and F-18-Fluorodeoxy glucose PET can help to distinguish between benign and malignant nodules and guides the physicians to a proper management strategy (6).

In the current review, we briefly reported the role of nuclear medicine in the management of SPN.

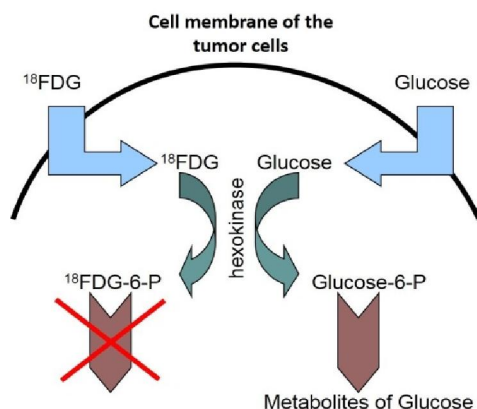
## Positron Emission Tomography (PET)

PET is the main imaging modality of the nuclear medicine discipline in oncology. Several PET tracers have been used for differentiation of malignant from benign SPN which 18-F-FDG is the main radiopharmaceutical.

### 18-F-FDG PET

Malignant cells have a higher metabolic rate than normal cells, with resultant higher glucose uptake. PET imaging uses the isotope fluorine-18 bound to a glucose analog to make F18-fluorodeoxy glucose (FDG). Increased FDG uptake is seen in most malignant tumors and it is the basis of the PET study to differentiate malignant from benign nodules (Figure 1).

FDG uptake can be quantified with standardized uptake value (SUV) to normalize variations of patients' weight and injected dose of the radioisotope. This semi quantitative method allows comparison of uptake between different lesions and different patients. SUV greater than



**Figure 1.** Metabolic pathways of Glucose and FDG in the tumor cells.

2.5 has been considered highly suspicious for malignancy (7). SUV is also a predictor of survival in patients with lung cancer and higher SUV was associated with poor outcome (8).

An additional advantage of FDG-PET imaging is better detection of mediastinal metastases and improving the staging of lung cancers (9).

Several meta-analyses have evaluated the accuracy of 18-F-FDG PET imaging for differentiating benign from malignant SPN.

The first meta-analysis published in 2001, showed pooled sensitivity and specificity of 96.8% and 77.8% respectively (10). The authors of the meta-analysis didn't find any difference between 18-F-FDG studies using dedicated PET cameras and Coincidence gamma cameras. It is worth mentioning that co-incidence cameras are not obsolete. False negative results are shown to be due to certain histopathologic types with low metabolic rate and 18-F-FDG uptake such as bronchioalveolar carcinoma and carcinoids and in small size nodules (smaller than 8 mm). False positive results are largely due to granulomatous and infectious diseases (11, 12).

PET/CT gamma cameras can also combine the functional images from PET section and morphologic data from CT section and would give better diagnostic accuracy (1).

The second meta-analysis was published in 2008 and evaluated the competing imaging modalities for differentiating malignant versus benign SPN (13). Pooled sensitivity and specificity for 18-F-FDG PET imaging was 95% and 82% respectively. Table 1 shows the results of this meta-analysis for all studied modalities. In another meta-analysis by the same group published in 2008, positive LRs for current diagnostic tools were 3.91 for CT-scan, 4.57 for MRI, 5.44 for 18-F-FDG PET and 5.16 for Tc-99m-Depreotide SPECT. Negative LRs for malignancy in SPN were 0.1 for CT-scan, 0.08 for MRI, 0.06 for 18-F-FDG PET and Tc-99m-Depreotide SPECT (14).

Another meta-analysis published in 2012 evaluated the diagnostic performance of dual-time 18F-FDG PET in diagnosing pulmonary nodules. The authors reported 85% pooled sensitivity and 77% pooled specificity and concluded that dual-time 18-F-FDG PET is not superior to single time conventional imaging.

Finally, the cost-effectiveness analysis of 18-F-FDG PET imaging in pulmonary nodules reported that PET imaging in the staging of NSCLC and diagnosis of SPNs is highly cost effective (15).

In conclusion, 18-F-FDG PET imaging is a highly accurate diagnostic method for differentiating benign versus malignant SPNs. The only short-coming of this imaging method is

**Table 1.** pooled diagnostic indices of different modalities for differentiation of benign from malignant SPN. The data is according to

	sensitivity	specificity	Positive predictive value	Negative predictive value	Diagnostic odds ratio	Area under SROC
Dynamic CT	93%	76%	80%	95%	39.91	0.93
MRI	94%	79%	86%	93%	60.59	0.94
18-F-FDG PET	95%	82%	91%	90%	97.31	0.94
99m-Tc-Depreotide SPECT	95%	82%	90%	91%	84.5	0.94

Cronin et al meta-analysis.

#### Other PET tracers

Another tracer for PET imaging is 11-C-methionine that seems to be more sensitive and specific than 18-F-FDG PET for differentiating benign from malignant nodules. SPNs with low 11-C-methionin uptake but high 18-F-FDG uptake are less likely to be malignant (16). Further studies are needed to confirm these results.

### SPECT imaging using conventional nuclear medicine radiotracers

#### Somatostatin receptor scintigraphy

Different radiopharmaceuticals are used for SPECT imaging to assess SPN potential for malignancy. Depreotide is a somatostatin analog peptide which can be labeled with 99m-Tc and has been shown to have affinity for somatostatin receptors (type2,3 and 5) expressed on non-small cell lung cancers (17).

In a study by Grewal and coworkers, the diagnostic value of technetium 99m-depreotide and computed tomography was compared. They showed that Tc-depreotide has better diagnostic accuracy (including sensitivity, specificity, positive and negative predictive values and accuracy) as compared to CT for assessment of malignancy in SPNs (18).

In a multicenter trial with 99m-Tc-depreotide for SPN evaluation, the sensitivity and specificity to detect malignancy in SPNs were 96.6% and 73.1% respectively (19).

As shown in Table 1, the diagnostic accuracy of 99m-Tc-Depreotide for differentiation of benign from malignant SPNs is comparable to 18-F-FDG PET imaging. This is the reason that Cronin et al in their meta-analysis concluded that 99m-Tc-Depreotide SPECT is a low cost and available modality for evaluation of SPN and can be readily used for this purpose (13, 14).

Another somatostatin analogue is EDDA/HYNIC-TOC which is labeled with technetium-99m and is available in our country for SPECT imaging. Several studies reported excellent results with this radiotracer too. For example Plachcinska et al showed that this tracer had better diagnostic value for malignancy detection in SPN as compared to 99m-Tc- depreotide

(20). This better diagnostic accuracy was due to slightly higher false positive results by 99m-Tc-Depreotide. These false positive results in somatostatin analogues imaging can be due to inflammatory reactions to foreign body or infectious process specially tuberculosis, abscess and suppurating lesions. In another study by Plachcinska et al, Semi quantitative assessment of Tc-EDDA/HYNIC TOC images was shown to be helpful to make a distinction between benign and malignant SPNs. They reported cut off value of 2 for tumor/background ratio for this purpose (21). This semi-quantitative method is very much the same as SUV in PET imaging and can increase the diagnostic accuracy of SPECT imaging too.

In conclusion, somatostatin receptor scintigraphy using SPECT method is highly reliable for differentiation of benign from malignant SPNs. The diagnostic accuracy is comparable to 18-F-FDG PET imaging. Again the short-coming of this modality is sub-optimal specificity especially in the tuberculosis endemic areas.

#### 201-Thalium

201-Thalium (Tl201) is a potassium analogue which can be used as a tumor marker especially for the brain tumors (22-24). This radiotracer has also been used for SPN evaluation by the SPECT method.

In an investigation by Nagamachi et al sensitivity, specificity, positive and negative predictive values and accuracy of Tl-201 SPECT were 76%, 95%, 97%, 63%, and 82% respectively (25). Another study by Komori et al evaluated the accuracy of breath hold Tl-201 SPECT in SPNs. They reported 80% sensitivity and 80% specificity (26).

In comparative evaluation of 99m-Tc-depreotide and 201-Tl SPECT for SPN, similar diagnostic accuracy for both modalities were shown by Boundas et al (27). Boundas et al also reported that semi-quantitative approach can increase the accuracy of imaging considerably.

In conclusion, Tl-201 is an available radiotracer for evaluation of SPNs. The accuracy of this modality seems to be lower than somatostatin receptor scintigraphy or 18-F-FDG PET.

### 99m-Tc-MIBI and 99m-Tc-tetrofosmin

Technetium-99m methoxy isobutyl isonitrile (MIBI) is a low cost and widely available radiopharmaceutical that shows increased uptake in malignant tumors including malignant SPNs (28-33).

In a research by Schuurmans and coworkers, the sensitivity and specificity of 92% and negative predictive value of 97% for malignancy detection in SPNs by 99m-Tc-MIBI SPECT were reported (34). Interestingly, Schuurmans et al study was performed in a tuberculosis endemic area where high false positive results are expected. It has been shown that 99m-Tc-MIBI has high uptake in active tuberculosis lesions which can decrease the specificity of this modality in SPN evaluation (35-39).

99m-Tc tetrofosmin is another tracer with the same properties of 99m-Tc-MIBI. This tracer also showed increased uptake in malignant SPNs and can be used for discriminating malignant from benign lesions with high sensitivity and accuracy (40).

In conclusion, 99m-Tc-MIBI and 99m-Tc-Tetrofosmin SPECT are useful alternative modalities with high accuracy for SPN evaluation when positron emission tomography is not available. Same as other modalities above, sub-optimal specificity is the major issue of these radiotracers too.

### Acknowledgements

This study was supported by the vice chancellor of research of Mashhad University of Medical Sciences. This manuscript is part of the residency thesis of the first author under the approval number of 900790 which was conducted in Nuclear Medicine Research Center of Mashhad University of Medical Sciences, Mashhad, Iran.

### Conflict of interests

The authors have no conflict of interests.

### References

1. Khan AN, Al-Jahdali HH, Irion KL, Arabi M, Koteyar SS. Solitary pulmonary nodule: A diagnostic algorithm in the light of current imaging technique. *Avicenna J Med.* 2011;1:39-51.
2. Hodnett PA, Ko JP. Evaluation and management of indeterminate pulmonary nodules. *Radiol Clin North Am.* 2012;50:895-914.
3. Jimborean G, Ianosi ES, Comes A, Budin C, Preda D. [Solitary pulmonary nodule: diagnosis criteria and management]. *Pneumologia.* 2009;58:211-218.
4. Meziane MA. Current concepts in imaging and management of the solitary pulmonary nodule. *J Med Liban.* 2009;57:17-25.
5. Hanley KS, Rubins JB. Classifying solitary pulmonary nodules. New imaging methods to distinguish malignant, benign lesions. *Postgrad Med.* 2003;114:29-35.
6. Meert AP. Pulmonary nodule: a bayesian approach. *Rev Med Brux.* 2010;31:117-121.
7. Grgic A, Yüksel Y, Gröschel A, Schäfers HJ, Sybrecht GW, Kirsch CM, et al. Risk stratification of solitary pulmonary nodules by means of PET using (18)F-fluorodeoxyglucose and SUV quantification. *Eur J Nucl Med Mol Imaging.* 2010;37:1087-1094.
8. Xiang ZL, Erasmus J, Komaki R, Cox JD, Chang JY. FDG uptake correlates with recurrence and survival after treatment of unresectable stage III non-small cell lung cancer with high-dose proton therapy and chemotherapy. *Radiat Oncol.* 2012;28:144.
9. Kozower BD, Meyers BF, Reed CE, Jones DR, Decker PA, Putnam JBJ. Does positron emission tomography prevent nontherapeutic pulmonary resections for clinical stage IA lung cancer? . *Ann Thorac Surg.* 2008;85:1166-1169.
10. Gould MK, Maclean CC, Kuschner WG, Rydzak CE, Owens DK. Accuracy of positron emission tomography for diagnosis of pulmonary nodules and mass lesions: a meta-analysis. *JAMA.* 2001;285:914-924.
11. Groheux D, Hindie E, Tredaniel J, Giraudet AL, Vaylet F, Berenger N, et al. [PET-CT for evaluation of the solitary pulmonary nodule: an update]. *Rev Mal Respir.* 2009;26:1041-1055.
12. Lee HY, Lee KS. Ground-glass opacity nodules: histopathology, imaging evaluation, and clinical implications. *J Thorac Imaging.* 2011;26:106-118.
13. Cronin P, Dwamena BA, Kelly AM, Carlos RC. Solitary pulmonary nodules: meta-analytic comparison of cross-sectional imaging modalities for diagnosis of malignancy. *Radiology.* 2008;246:772-782.
14. Cronin P, Dwamena BA, Kelly AM, Bernstein SJ, Carlos RC. Solitary pulmonary nodules and masses: a meta-analysis of the diagnostic utility of alternative imaging tests. *Eur Radiol.* 2008;18:1840-1856.
15. Cao JQ, Rodrigues GB, Louie AV, Zaric GS. Systematic review of the cost-effectiveness of positron-emission tomography in staging of non--small-cell lung cancer and management of solitary pulmonary nodules.



- Clin Lung Cancer. 2012;13:161-170.
16. Hsieh HJ, Lin SH, Lin KH, Lee CY, Chang CP, Wang SJ. The feasibility of <sup>11</sup>C-methionine-PET in diagnosis of solitary lung nodules/masses when compared with <sup>18</sup>F-FDG-PET. *Ann Nucl Med*. 2008;22:533-538.
  17. Chcialowski A, Dziuk E, From S, Plusa T, Lubinski W, Pietrzykowski J, et al. [Technetium<sup>99</sup> labelled synthetic somatostatin analogue (depreotide) in the diagnosis of peripheral solitary pulmonary nodules]. *Pol Arch Med Wewn*. 2004;112:1031-1038.
  18. Grewal RK, Dadparvar S, Yu JQ, Babaria CJ, Cavanaugh T, Sherman M, et al. Efficacy of Tc-<sup>99m</sup> depreotide scintigraphy in the evaluation of solitary pulmonary nodules. *Cancer J*. 2002;8:400-404.
  19. Blum J, Handmaker H, Lister-James J, Rinne N. A multicenter trial with a somatostatin analog (<sup>99m</sup>Tc depreotide) in the evaluation of solitary pulmonary nodules. *Chest*. 2000;117:1232-1238.
  20. Plachcinska A, Mikolajczak R, Kozak J, Rzeszutek K, Kusmierek J. Comparative analysis of <sup>99m</sup>Tc-depreotide and <sup>99m</sup>Tc-EDDA/HYNIC-TOC thorax scintigrams acquired for the purpose of differential diagnosis of solitary pulmonary nodules. *Nucl Med Rev Cent East Eur*. 2006;9:24-29.
  21. Plachcinska A, Mikolajczak R, Kozak J, Rzeszutek K, Kusmierek J. A visual and semi-quantitative assessment of (<sup>99m</sup>Tc-EDDA/HYNIC-TOC scintigraphy in differentiation of solitary pulmonary nodules. *Nucl Med Rev Cent East Eur*. 2004;7:143-150.
  22. Nagai H, Haramoto M, Takada D, Daisu M, Miyazaki T, Sugimoto K, et al. [Quantitative assessment of the usefulness of MR-fusion Tl-SPECT image in the diagnosis of brain tumor]. *No Shinkei Geka*. 2008;36:1093-1101.
  23. Terada H, Kamata N. Contribution of the combination of (<sup>201</sup>Tl SPECT and (<sup>99m</sup>Tc)O(4)(-) SPECT to the differential diagnosis of brain tumors and tumor-like lesions. A preliminary report. *J Neuroradiol*. 2003;30:91-94.
  24. Di Giuda D, Valenza V, Di Giuda A, De Rossi G, David V. Tl-201 brain SPECT in glomus jugulare tumor. *Clin Nucl Med*. 2003;28:340-342.
  25. Nagamachi S, Jinnouchi S, Nishii R, Futami S, Tamura S, Matsuzaki Y, et al. [Reevaluation of <sup>201</sup>Tl-SPECT for patients with solitary pulmonary nodule--comparison study with biopsy method and tumor marker measurement]. *Kaku Igaku*. 2001;38:737-45.
  26. Komori T, Narabayashi I, Hayashi M, Horiuchi S, Adachi I, Ogura Y, et al. Evaluation of breath-hold <sup>201</sup>Tl SPECT in the differential diagnosis of solitary pulmonary nodules. *Ann Nucl Med*. 2005;19:277-281.
  27. Boundas D, Karatzas N, Moravidis E, Arsos G, Drevelengas A, Pisteovou-Gompaki K, et al. Comparative evaluation of <sup>99m</sup>Tc-depreotide and <sup>201</sup>Tl chloride single photon emission tomography in the characterization of pulmonary lesions. *Nucl Med Commun*. 2007;28:533-540.
  28. Chen J, Chang J, Lew P, Vasinrapee P, Shim JJ. Nuclear scintigraphy findings for Askin tumor with In<sup>111</sup>-pentetretotide, Tc<sup>99m</sup>-MIBI and F<sup>18</sup>-FDG. *J Radiol Case Rep*. 2012;6:32-39.
  29. Treglia G, Caldarella C, Saggiorato E, Ceriani L, Orlandi F, Salvatori M, et al. Diagnostic performance of (<sup>99m</sup>Tc-MIBI scan in predicting the malignancy of thyroid nodules: a meta-analysis. *Endocrine*. 2013;44:70-78.
  30. Krolicki L, Cwikla JB, Timorek A, Ruszczynska M, Stelmachow J, Sawicki W, et al. Technetium-<sup>99m</sup> MIBI imaging in diagnosis of pelvic and abdominal masses in patients with suspected gynaecological malignancy. *Nucl Med Rev Cent East Eur*. 2002;5:131-137.
  31. Carril JM, Gomez-Barquin R, Quirce R, Tabuenca O, Uriarte I, Montero A. Contribution of <sup>99m</sup>Tc-MIBI scintimammography to the diagnosis of non-palpable breast lesions in relation to mammographic probability of malignancy. *Anticancer Res*. 1997;17:1677-1681.
  32. Nikoletic K, Lucic S, Peter A, Kolarov V, Zeravica R, Srbovan D. Lung <sup>99m</sup>Tc-MIBI scintigraphy: impact on diagnosis of solitary pulmonary nodule. *Bosn J Basic Med Sci*. 2011;11:174-179.
  33. Minai OA, Raja S, Mehta AC, Sullivan EJ, Khan SU, Dasgupta A, et al. Role of Tc-<sup>99m</sup> MIBI in the evaluation of single pulmonary nodules: a preliminary report. *Thorax*. 2000;55:60-62.
  34. Schuurmans MM, Ellmann A, Bouma H, Diacon AH, Dyckmans K, Bolliger CT. Solitary pulmonary nodule evaluation with <sup>99m</sup>Tc-methoxy isobutyl isonitrile in a tuberculosis-endemic area. *Eur Respir J*. 2007;30:1090-1095.
  35. Raziei G, Masjedi MR, Fotouhi F, Asli NI, Shafiei B, Javadi H, et al. The role of <sup>99m</sup>Tc-MIBI scintigraphy in the management of

- patients with pulmonary tuberculosis. *Eur Rev Med Pharmacol Sci.* 2012;16:622-629.
36. Stefanescu C, Rusu V, Azoicai D, Hurjui I. <sup>99m</sup>Tc isonitrils biophysical aspects in pulmonary tuberculosis. Part II. In vitro evaluation of <sup>99m</sup>Tc MIBI cellular uptake mechanism. *Rev Med Chir Soc Med Nat Iasi.* 2007;111:210-215.
  37. Stefanescu C, Rusu V, Boisteanu D, Azoicai D, Costin M, Oleniuc D, *et al.* <sup>99m</sup>Tc isonitrils biophysical aspects in pulmonary tuberculosis. Part I. In vivo evaluation of <sup>99m</sup>Tc MIBI and <sup>99m</sup>Tc Tetrofosmin biophysical localization mechanisms. *Rev Med Chir Soc Med Nat Iasi.* 2006;110:944-949.
  38. Onsel C, Sonmezoglu K, Camsari G, Atay S, Cetin S, Erdil YT, *et al.* Technetium-99m-MIBI scintigraphy in pulmonary tuberculosis. *J Nucl Med.* 1996;37:233-238.
  39. Ahmadihosseini H, Sadeghi R, Zakavi R, Kakhki VR, Kakhki AH. Application of technetium-99m-sestamibi in differentiation of active from inactive pulmonary tuberculosis using a single photon emission computed tomography method. *Nucl Med Commun.* 2008;29:690-694.
  40. Spanu A, Schillaci O, Pirina P, Arru A, Madeddu G, Chessa F, *et al.* <sup>99m</sup>Tc-tetrofosmin SPECT in solitary pulmonary nodule evaluation. *Oncol Rep.* 2006;16:763-769.