

## Indication of Flexible Fiberoptic Bronchoscopy and the Histopathological Examination in 500 Patients

Seyed Hossein Ahmadi Hosseini<sup>1\*</sup>, Fariba Rezaeetalab<sup>1</sup>

<sup>1</sup> Pulmonologist, Lung Disease research Center, Mashhad University of Medical Sciences, Mashhad, Iran

### ARTICLE INFO

Article type:  
Original Article

Article history:  
Received: 07 Aug 2017  
Revised: 05 Jan 2018  
Accepted: 08 Feb 2018

Keywords:  
Flexible Fiberoptic Bronchoscopy  
Histopathology  
Indications  
Lung Cancer  
Tuberculosis

### ABSTRACT

**Introduction:** The importance of flexible fiberoptic bronchoscopy (FFB) for diagnosis of pulmonary diseases is well known. The aim of this study was to evaluate the indications of 500 FFBs performed in Imam Reza hospital, Mashhad, Iran as well as examination of the histopathological and radiological findings.

**Material and Methods:** This was a retrospective analysis of the medical records and chest radiologic examinations of 500 patients who had undergone FFB using Olympus BFP20 instrument by local anesthesia in, Mashhad, Iran. The indications for procedures, demographic data, and clinical symptoms were recorded and analyzed in addition to radiological and histopathological findings.

**Results:** The most common indication for FFB was found to be bronchogenic carcinoma (n=20), followed by tuberculosis (TB; n=16), sarcoidosis (n=2), and hydatid cyst (n=2). A total of 70 anthracosis cases were reported to be accompanied with other pulmonary disorders and findings such as chronic granulomatous bronchitis suspicious of TB (n=16), squamous cell carcinoma (SCC; n=5), non-specific macrophage cells in cytology (n=19), anthracotic pigment with no risk of lung cancer (n=20), anthracofibrosis (n=4), severe anthracotic pigment with undetectable mucus layer (n=2), anthracotic pigment with non-specific inflammation (n=1), mild squamous metaplasia (n=1), and chronic bronchitis with mild squamous metaplasia (n=2). Lung cancer showed higher frequency in women and patients in the sixth and seventh decades of their lives and was associated with smoking. It is worthy to note that SCC was the most prevalent cancer among the smokers. Twenty cases were diagnosed as bronchogenic carcinoma by clinical findings, eighteen of which also being confirmed by the histological examinations. Moreover, two cases of sarcoidosis diagnosis using FFB were approved by biopsy. Out of 297 bronchial biopsies, the most common indication for FFB were airway collapse and unknown pulmonary opacity.

**Conclusion:** Considering the important role of FFB in the diagnosis of pulmonary diseases, especially cancers, it seems that various diagnostic measures should be taken into consideration before disease progression. According to our evaluations, patient screening by the family physicians is recommended for the patients with cancer or TB as the two most prevalent diseases in our study.

► Please cite this paper as:

Ahmadi Hosseini SH, Rezaeetalab F. Indication of Flexible Fiberoptic Bronchoscopy and the Histopathological Examination in 500 Patients. J Cardiothorac Med. 2018; 6(1): 251-257.

## Introduction

Bronchoscopy is the current gold standard for visualizing inside of the airways and determine

\*Corresponding author: Seyed Hossein Ahmadi Hosseini, Lung Disease Research Center, Mashhad University of Medical Sciences, Mashhad, Iran. Tel: +985138598818; Fax: +985138598818; Email: Ahmadihh@mums.ac.ir

© 2018 *mums.ac.ir* All rights reserved.

This is an Open Access article distributed under the terms of the Creative Commons Attribution License (<http://creativecommons.org/licenses/by/3.0>), which permits unrestricted use, distribution, and reproduction in any medium, provided the original work is properly cited.

the exact occurrence rate, reasons, and severity of the airways obstruction (1). Use of flexible fiberoptic bronchoscopy (FFB) as an effective and minimally invasive technique for diagnosis and management process in a variety of lung diseases have greatly increased due to its low morbidity and mortality rates (2). Today, FFBs allow direct visualization of the airways, which have diameters of less than 2 mm (3). There are numerous indications for bronchoscopy including atelectasis, persistent local wheezing, peripheral pulmonary nodule, hemoptysis, chronic cough, pleural effusion, recurrent and unresolved pneumonia, and tuberculosis (TB) (4). Although flexible bronchoscopy is generally considered as a safe procedure, some complications might be encountered during or after the bronchoscopy such as hypoxemia, bronchospasm, seizure, laryngeal spasm, laryngeal edema, pneumothorax, septicemia, bacteremia, airway obstruction, respiratory arrest, hemorrhage, vomiting, arrhythmia, and cardiovascular collapse (5). Here we reviewed retrospectively the indications, outcomes, and complications of FFB in 500 patients who referred to Imam Reza hospital, Mashhad, Iran and the results were compared with the global statistics. Also the relationship correlations between bronchoscopic findings and the demographic characteristics, clinical presentation, and histopathological examination were investigated.

## Materials and Methods

### Patients

In this retrospective study, total of 500 patients who underwent FFB at the Respiratory Endoscopy Section of Internal Department in Imam Reza Hospital, Mashhad, Iran were selected. The patients were either from the internal or surgery wards or were referrals from other hospitals and were examined by the FFB for various reasons such as hemoptysis, chronic cough, fever, sweating, and abnormal radiological findings suspicious of having lung cancer.

It should be noted that the FFB was performed by a pulmonologist and the reports were completed containing the patient's demographic data, history of cigarette smoking, duration of symptoms, premeditation, indications, chest X ray, cytological and histopathological findings, complications/prognosis.

### Ethical Considerations

Informed consents were obtained from the patients prior to the procedure and the study was approved by the Research Ethics Committee of Mashhad University of Medical Sciences, Iran. Patients who refused bronchoscopy and those

with incomplete data or severe hypoxia were excluded from the study.

### Bronchoscopy

Prior to the bronchoscopy procedure, lateral and frontal chest X-ray examinations, spirometry, arterial blood gas analysis, and electrocardiography were performed. If needed, high resolution Computerized Tomography (CT) scan was also carried out in some cases. Bleeding time, prothrombin time, partial thromboplastin time, and platelet count were all assessed if transbronchial lung biopsy (TBLB), endobronchial biopsy, or brushings were supposed to be executed.

Finally, the FFB was carried out using bronchoscopes (BF 1T150 or BF XT240 models, Olympus Medical Systems Corporation, Tokyo, Japan) with outer diameters of 5.3 to 5.4 mm and working lengths of 600 mm under local anesthesia with lidocaine 10% spray, in most cases through the transnasal route in the supine position.

Briefly, following the local anesthesia of nasal and oropharynx, the FFB examination of vocal cords, upper airways and the tracheobronchial tree was performed. After thorough examination of the bronchial tree, biopsies were taken from the lesions. If the airways were clean, bronchoalveolar lavage (BAL) was performed with NaCl solution in patients with abnormal CT scan or radiological findings to collect samples for cytology examination, smear, and culture for *Burkholderia cepacia* complex. The TBLB was applied blindly (i.e., without fluoroscopy guide) in the selected patients.

Afterwards, the BAL fluid and secretions were collected for cytological and microbiological analysis. The TBLB or endobronchial biopsies were collected for the histopathology examinations. None of the patients underwent bronchial brushing. During the FFB all the patients were continuously monitored with electrocardiogram (ECG) and pulse oximeter. Suction was stopped and the bronchoscope was withdrawn when oxygen saturation was low and did not return to normal.

Fortunately, in this study we did not confront any significant problematic complications. Hypoxia during the bronchoscopy was corrected by reducing the suction and trying autotherapy. Hemoptysis did not occur during the bronchoscopy, although there was very little bleeding during the TBLB which was controlled effectively.

### Statistical analysis

The collected data were entered into MS Excel 97 for windows XP professional. The results were presented as median and mean percentage values and standard deviation or range.

## Results

### Demographic Data

A total of 500 bronchoscopies were performed, most of which being diagnostic and only a few of them were carried out for therapeutic purposes. Out of the 500 patients, 235 were males and 265 individuals were females. Age of the studied patients ranged from 20 to 80 years with a mean of 50 years.

The frequency of age groups of over 70, 60-70, 50-60, 40-50, 30-40, and under 30 years of were 167, 158, 70, 30, 38, and 38 cases, respectively.

About 150 (30 %) patients had a history of cigarette smoking and 49 (33%) individuals among them had cancer.

### Clinical Presentation and Radiological Findings

Clinical symptoms of the patients at the time of referral are presented in Figure 1. A total of 81 (16.2%) patients had lung cancer. As shown in Figure 2, frequency of different cancers

among the patients with smoking habit was as squamous cell carcinoma (SCC) in 37 (25%) cases, small cell lung cancer (SCLC) in ten (20.4%) patients, and adenoid cystic carcinoma (ACC) in two individuals. None of the patients with large-cell carcinoma (LCC) used to smoke cigarette.

The erythrocyte sedimentation rate (ESR) results documented in the medical records of the 101 patients represented 39 (38.61%), 35 (34.65%), 56 (55.44%), 25 (24.75%), and 25 (24.75%) of the patients as ESRs of <20 mm/h, 20-40 mm/h, 40-60 mm/h, 60-80 mm/h, and 80-100 mm/h, respectively.

Moreover, 38 cases (37.62%) with ESRs of higher than normal interval were reported to demonstrate histological findings including SCC, ACC, SCLC, TB, chronic bronchitis, and hydatid cyst in eight (21%), five (13.15%), five (13.15%), one (2.6%), one (2.6%), and one (2.6%) individuals, respectively. Thirteen cases (34.21%) had normal results and one (2.6%)

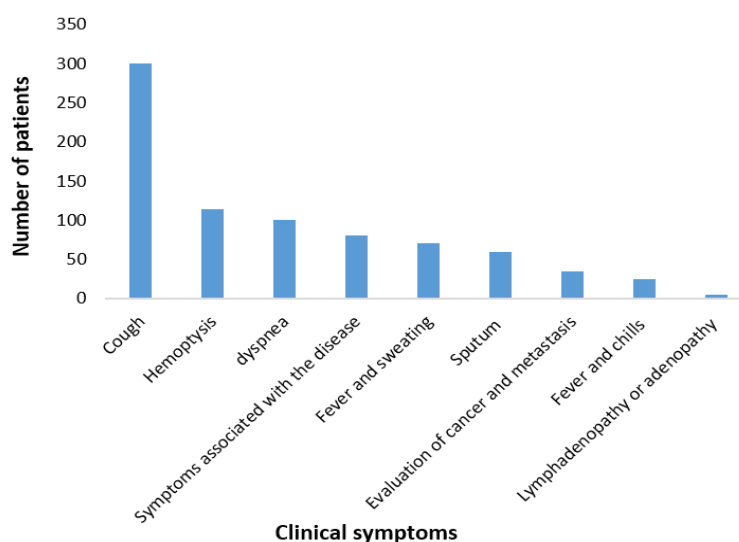


Figure 1. Clinical symptoms of the patients at referral time

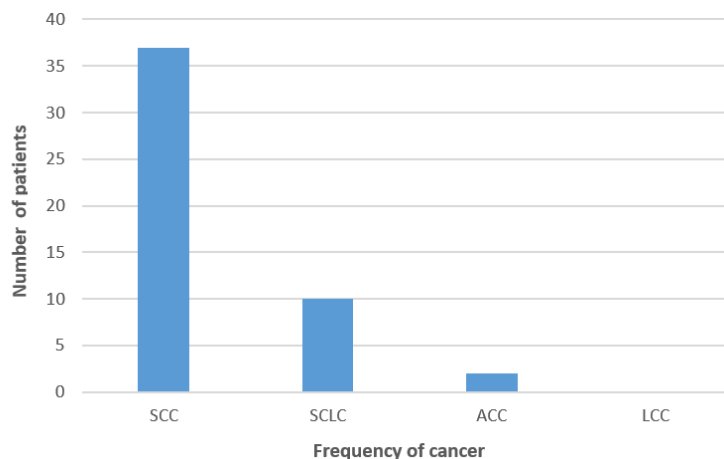


Figure 2. Frequency of the different cancers among the smoker patients

**Table 1.** Frequency of the radiological findings

Symptoms	Patients No (%)
Opacity	300 (60%)
Pulmonary infiltration	46 (9.2%)
Effusion	20 (4%)
Obstructive collapse	19 (3.8%)
Mediastinal changes	15 (3%)
Bronchiectasis	12 (2.4%)
Pulmonary mass	9 (1.8%)
Lymphadenopathy	6 (1.2%)
Loss of lung volume	5 (1%)
Miliary lung shadows	4 (0.8%)
Interstitial lung disease	1 (0.2%)
Combined type	0 (0%)
Normal	20 (4%)

was affected with severe anthracosis. Table 1 summarizes the radiological findings of the studied patients. The erythrocyte sedimentation rate (ESR) results documented in the medical records of the 180 patients represented 39 (21.66%), 35 (19.44%), 56 (31.11%), 25 (13.88%), and 25 (13.88%) of the patients as ESRs of <20 mm/h, 20-40 mm/h, 40-60 mm/h, 60-80 mm/h, and 80-100 mm/h, respectively. Moreover, 35 cases (19.44%) with ESRs of higher than normal interval were reported to demonstrate histological findings including SCC, ACC, SCLC, TB, chronic bronchitis, and hydatid cyst in eight (22.85%), five (14.28%), five (14.28%), one (2.8%), one (2.8%), and one (2.8%) individuals, respectively. Thirteen cases (37.14%) had normal results and one (2.8%) was affected with severe anthracosis. Regions of homogenous and non-homogenous opacity in all the 500 patients, who underwent the FFB, are shown in Table 2.

**Table 2.** Regions of homogenous and non-homogenous opacity in the 500 flexible fiberoptic bronchoscopy patients

Area	Opacity	
	Homogenous No (%)	Non-homogenous No (%)
Right middle lobe	46 (15.3%)	23 (7.7%)
Right lower lobe	42 (14%)	16 (5.3%)
Upper right lobe	32 (10.7%)	13 (4.3%)
Upper left lobe	15 (5%)	12 (4%)
Left lower lobe	15 (5%)	9 (3%)
Left middle lobe	12 (4%)	8 (2.7%)
Left perihilar region	12 (4%)	5 (1.7%)
Right paratracheal region	5 (1.7%)	2 (0.4%)
Right paracardiac region	4 (1.3%)	2 (0.4%)
Left paracardiac region	2 (0.7%)	2 (0.4%)
Left paratracheal region	1 (0.3%)	0

### Bronchoscopic findings

Bronchoscopy was diagnostic in 40 (8%) patients including 20 cases (4%) with cancer, two

cases (0.4%) of sarcoidosis, 16 cases (3.2%) of TB, and two cases (0.4%) of hydatid cyst. Comparison was made between the bronchoscopic and pathological findings. Eighteen of the twenty cancer cases diagnosed by bronchoscopy were confirmed to be SCC by histopathology and biopsy was reported as normal in the other two patients. Two cases, which were diagnosed as hydatid cyst by bronchoscopy, were also confirmed by the histopathological evaluation.

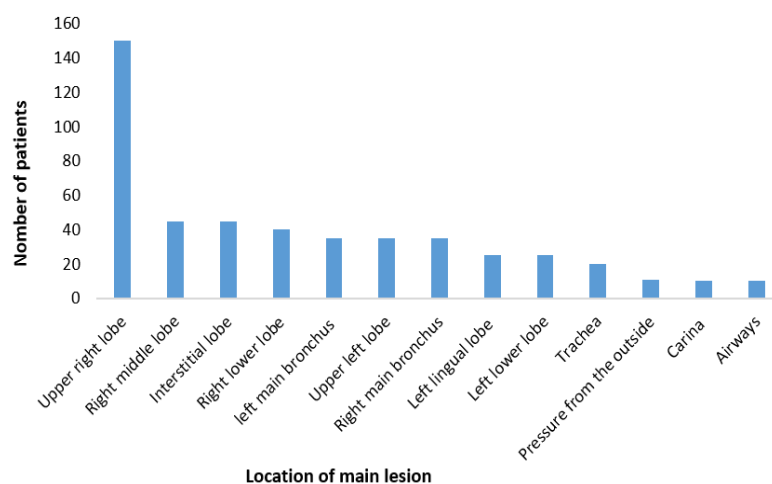
Regarding sarcoidosis identification, the two methods were not consistent and histopathology did not affirm the positive result of bronchoscopy. In case of TB, six out of the sixteen TB diagnoses by bronchoscopy were also approved by the histopathological findings while four individuals had a normal biopsy and biopsy examination was not requested in 6 cases.

Anthracosis was observed in 70 patients in addition to the other pulmonary abnormalities. These patients included twenty anthracotic pigment cases without lung cancer risk, nineteen cases of unknown specific cytology, sixteen chronic granulomatous bronchitis cases suspicious of TB, five SCCs, four anthracofibrosis, two severe anthracotic pigment cases with undetectable mucus layer, two chronic bronchitis with mild squamous metaplasia, one anthracotic pigment with non-specific inflammation, and one mild squamous metaplasia.

Figure 3 demonstrates the location of main lesions observed by the flexible bronchoscopy in the patients. In cytological examinations, 180 patients were normal, 150 patients had inflammatory polynuclear cells without metaplasia. Additionally, 60 patients were suspicious of malignancy in cytology due to the scattered neoplastic cells with unequal hyperchromatic nuclei, some vacuoles, and increased nucleus to cytoplasm ratio.

Moreover, 46 patients showed inflammatory metaplastic polynuclear cells in cytology, 15 cases had abundant mature squamous cells and small squamous cells without neoplastic cells. Cytology slides of seventeen patients contained abundant mature squamous cells and small squamous cells with neoplastic cells and eight patients had hydatid cyst fluid with abundant hooklet and calcium deposits.

Bronchial biopsy was taken from 297 cases out of the 500 bronchoscopy examinations. According to the histopathology results of the biopsy specimens 120 patients were normal. On the other hand, cancer, granulomatous bronchitis suspicious of TB, chronic bronchitis with metaplasia, and hydatid cyst were reported by histopathology



**Figure 3.** Locations of the main lesions in evaluation by flexible fiberoptic bronchoscopy

in 81 (27.27%), 38 (12.79%), 50 (16.83%), and eight (2.7%) individuals, respectively. Among the 85 patients at initial stages of cancer, 49 cases (60.4%) were reported to have SCC, 19 (23.1%) had SCLC, 10 (12%) had ACC, and three cases (3.5%) were diagnosed as large-cell carcinoma (LCC). Among the 81 patients at initial stages of cancer, 49 cases (60.49%) were reported to have SCC, 19 (23.45%) had SCLC, 10 (12.34%) had ACC, and three cases (3.7%) were diagnosed as large-cell carcinoma (LCC).

### Complications

Fortunately, in this study we did not confront any remarkable complications. Hypoxia during the bronchoscopy was corrected by autotherapy and reducing the suction. Hemoptysis did not occur during the bronchoscopy; however, there was very little bleeding during the TBLB which was controlled effectively.

### Discussion

The importance of bronchoscopy in detection of different pulmonary diseases is absolutely clear (6). In the present study, the most common indication of FFB was lung cancer (50%), although it was also important for diagnosis of the other respiratory diseases. This finding is consistent with the previous studies performed in Nigeria, Switzerland, and India (7-9).

In this study, bronchial biopsy was requested for 293 cases out of 500 bronchoscopies. Of these biopsies, 81 cases were diagnosed to have bronchial cancer accounting for 27% of the biopsies. The most common age group with bronchogenic carcinoma was found to be the sixth and seventh decades of life. These results are comparable with the previous studies performed in other countries (8,10).

Regarding the gender distribution of the patients, 43 of the 81 lung cancer patients were

females and 38 were males, which is not consistent with the literature in other countries (9,4,10). This is likely due to the lower number of cases with cancer investigated in this study compared to the global statistics. Another reason could be that in the developing countries such as Iran, men are responsible for paying most of the expenses in a family while follow-up and treatment of a disease may lead to unemployment and ultimately, loss of the family's income. Therefore, they may not refer to a doctor until they are not in difficult situations and progressed stages of the disease. On the other hand, females take the disease more serious and refer to a doctor sooner. Moreover, tobacco use is of high prevalence among the women.

The most common etiology of the primary lung cancer is smoking cigarette (11). Among all the cancer cases, 49 were smokers, of whom 33 were males and sixteen were females. According to our findings, 60.5% of the patients with primary lung cancer were smokers and female smokers were half of the males. These results obtained from the current study do not differ significantly from the statistics of other countries and the small differences can be neglected due to the low number of smokers with cancer studied in the current study compared to the previous studies (12,13,10).

In the current study, SCC was the most common cancer related to smoking habit and LCC and ACC were less associated with smoking cigarette. This finding is also in agreement with the results of other studies (14,15,10).

In this study, the most common clinical symptoms at presentation were cough, dyspnea, hemoptysis, fever, and sweating, which are in line with the results of most studies (16-18). Unfortunately, patients with lung cancer who used opium simultaneously with cigarette was

less coughing, mainly due to the effects of opium on the cough receptors.

Elevated ESR as a marker of systemic inflammation is often observed in patients with infection, malignancy, and autoimmune diseases (19).

Recently, it was demonstrated that raised ESR could be associated with pulmonary impairment rather than the conventional measures of muscle inflammation in the patients with myositis (20).

In the current study, eighteen patients had ESRs higher than 80 mm/h. It should be noted that ESR alterations were documented in the medical records of only 37 cases with bronchogenic carcinoma.

Opacity was the most common chest radiography finding in this study followed by pulmonary infiltration, effusion, obstructive collapse, bronchiectasis, pulmonary mass, and lymphadenopathy. Radiological findings were consistent with other tests in some reports, and inconsistent in others which might be due to the different referral times (18,4).

In this study, right upper lobe was the most common site of involvement. The mentioned result is in accordance with the literature (10,21). This pattern is likely associated with the changes in vascular, lymphatic, and anatomic structures (21) and could as well be due to the proximity of the first division after carina in the right side.

A valuable finding of the present study is confirmation of the clinical diagnosis through histopathological examination. Eighteen cases (90%) out of the twenty bronchogenic carcinomas diagnosed by bronchoscopy were also confirmed by the histological specimens. As a result, the importance of clinical and bronchoscopic examinations is highlighted, especially when histopathology is ambiguous.

In line with the results of previous studies, the SCC was the most commonly diagnosed cancer followed by the SCLC in contrary to the LCC, which had the lowest prevalence (14,15,13). Moreover, histopathological evaluation confirmed the bronchoscopic diagnosis of 38 cases with granulomatous inflammation, among which eighteen cases were suspected to be TB or sarcoidosis.

It seems that concerning the relatively high infection rate and frequency of TB in this region (22), the prevalence rate of 12.79% cannot be real. It should be mentioned that firstly, bronchoscopy is less commonly used for TB diagnosis and it is generally performed when the other methods fail to prove the disease. Secondly, since smears and TB bacillus cultures are the most definitive diagnostic methods for

TB and are available as simpler methods, biopsy is not usually necessary. In addition, approximately 20-30% of the TB cases present as extra-pulmonary involvements and the obtained statistics might not indicate the actual prevalence of TB.

In this study hydatid cysts of the 297 bronchoscopic cases with biopsy, 8 patients had hydatid cysts, among 297 bronchoscopic cases with biopsy in this study, 8 patients had hydatid cysts 2 of which were clinically diagnosed as hydatid cysts and confirmed by the biopsy.

Sarcoidosis was detected clinically in two cases and both were approved by the histopathological examination.

In Iran, sarcoidosis has a lower prevalence when compared to the TB, which is the same as some other countries such as India, Nepal, and Saudi Arabia (23,6,8).

Anthracois as another finding of FFB was detected in 70 cases (14%) accompanied with other pulmonary abnormalities such as chronic granulomatous unilateral bronchitis suspicious of TB, SCC, anthracofibrosis, mild squamous metaplasia, and chronic bronchitis with mild squamous metaplasia. The prevalence of simple anthracosis in the previous works has reported to be 3.4 - 21%, which is in line with our findings (24).

## Conclusion

In summary, our finding of smoking-associated bronchogenic carcinoma as the most common bronchoscopic detection was consistent with the previous studies. Lung cancer was more frequent in females and in the seventh and sixth decades of life. The lesions of lung cancer were more commonly found in the upper lobe of both sides with the higher frequency in the right lung. Furthermore, the SCC was the most common malignancy followed by the SCLC and LCC, which demonstrated the lowest prevalence. The histological examination confirmed most of the bronchogenic carcinoma cases diagnosed by bronchoscopy. Cough, dyspnea, hemoptysis, fever, and sweating were the frequent clinical symptoms at the presentation.

## Acknowledgments

None.

## Conflict of Interest

The authors declare no conflict of interest.

## References

1. Calloway HE, Kimbell JS, Davis SD, Retsch-Bogart GZ, Pitkin EA, Abode K, et al. Comparison of endoscopic versus 3D CT derived airway measurements. *Laryngoscope*. 2013; 123:2136-41.

2. Tang LF, Chen ZM. Fiberoptic bronchoscopy in neonatal and pediatric intensive care units: a 5-year experience. *Med Princ Pract.* 2009; 18:305-9.
3. Rodriguez AN. Flexible bronchoscopy. In: Díaz-Jimenez JP, Rodriguez AN, editors. *Interventions in pulmonary medicine.* New Springer; 2017. P. 13-34.
4. Alamoudi OS, Attar SM, Ghabrah TM, Kassimi MA. Bronchoscopy, indications safety and complications. *Saudi Med J.* 2000; 21:1043-47.
5. Singh V, Singhal KK. The tools of the trade - uses of flexible bronchoscopy. *Indian J Pediatr.* 2015; 82:932-7.
6. Alzeer AH, Al-Otair HA, Al-Hajjaj MS. Yield and complications of flexible fiberoptic bronchoscopy in a teaching hospital. *Saudi Med J.* 2008; 29:55-9.
7. Joos L, Patuto N, Chhajed PN, Tamm M. Diagnostic yield of flexible bronchoscopy in current clinical practice. *Swiss Med Wkly.* 2006; 136:155-9.
8. Gupta AA, Sehgal IS, Dhooria S, Singh N, Aggarwal AN, Gupta D, et al. Indications for performing flexible bronchoscopy: trends over 34 years at a tertiary care hospital. *Lung India.* 2015; 32:211-5.
9. Adewole OO, Onakpoya UU, Ogunrombi AB, Komolafe A, Odeyemi AD, Adeniran S, et al. Flexible fiberoptic bronchoscopy in respiratory care: diagnostic yield, complications, and challenges in a Nigerian Tertiary Center. *Niger J Clin Pract.* 2017; 20:77-81.
10. Rabahi MF, Ferreira AA, Reciputti BP, Matos Tde O, Pinto SA. Fiberoptic bronchoscopy findings in patients diagnosed with lung cancer. *J Bras Pneumol.* 2012; 38:445-51.
11. Furrukh M. Tobacco smoking and lung cancer: perception-changing facts. *Sultan Qaboos Univ Med J.* 2013; 13:345-58.
12. Gonzalez M, Vignaud JM, Clement-Duchene C, Luc A, Wild P, Bertrand O, et al. Smoking, occupational risk factors, and bronchial tumor location: a possible impact for lung cancer computed tomography scan screening. *J Thorac Oncol.* 2012; 7:128-36.
13. Maasdorp SD, Prins M, Van Rooyen C. Demographic profile of lung cancer patients at the universitas academic hospital bronchoscopy unit in bloemfontein: brief report. *South Afr J Epidemiol Infect.* 2012; 27:130-2.
14. Shrestha HG, Chokhani R, Dhakhwa R. Clinicopathologic profile of bronchogenic carcinoma. *JNMA J Nepal Med Assoc.* 2010; 49:100-3.
15. Suliman MI, Jibrán R, Majeed MZ. Demographics of bronchogenic carcinoma patients and frequency of cell types. *GJMS.* 2004; 4:2-6.
16. El-Khushman H, Momani JA, Sharara AM, Haddad FH, Hijazi MA, Hamdan KA, et al. The pattern of active pulmonary tuberculosis in adults at King Hussein Medical Center, Jordan. *Saudi Med J.* 2006; 27:633-6.
17. Yanardag H, Tetikkurt C, Tetikkurt S, Demirci S, Karayel T. Computed tomography and bronchoscopy in endobronchial tuberculosis. *Can Respir J.* 2003; 10:445-8.
18. Kaparianos A, Argyropoulou E, Sampsonas F, Zania A, Efremidis G, Tsiamita M, et al. Indications, results and complications of flexible fiberoptic bronchoscopy: a 5-year experience in a referral population in Greece. *Eur Rev Med Pharmacol Sci.* 2008; 12:355-63.
19. Go DJ, Lee EY, Lee EB, Song YW, Konig MF, Park JK. Elevated erythrocyte sedimentation rate is predictive of interstitial lung disease and mortality in dermatomyositis: a korean retrospective cohort study. *J Korean Med Sci.* 2016; 31:389-96.
20. Park JK, Gelber AC, George M, Danoff SK, Qubti MA, Christopher-Stine L. Pulmonary impairment, not muscle injury, is associated with elevated ESR in the idiopathic inflammatory myopathies. *Rheumatology (Oxford).* 2013; 52:1336-8.
21. Thakur A, Gao L, Ren H, Yang T, Chen T, Chen M. Descriptive data on cancerous lung lesions detected by auto-fluorescence bronchoscope: a five-year study. *Ann Thorac Med.* 2012; 7:21-5.
22. Akhavan R, Meshkat Z, Khajekaramadini M, Meshkat M. Eight-year study of Mycobacterium tuberculosis in mashhad, northeast of iran. *Iran J Pathol.* 2013; 8:73-80.
23. Devkota KC, Pathak R, Khanal A, Chokhani R. Fiberoptic bronchoscopy: seven-year experience at Nepal Medical College Teaching Hospital. *Nepal Med Coll J.* 2010; 12:260-3.
24. Mirsadraee M. Anthracosis of the lungs: etiology, clinical manifestations and diagnosis: a review. *Tanaffos.* 2014; 13:1-13.