

Pulmonary Thromboembolism as a Complication of an Electrophysiological Study: A Case Report

Mahnaz Mozdourian¹, FaribaRezaeetalab*¹

¹ Pulmonologist, Lung Diseases Research Center, Mashhad University of Medical Sciences, Mashhad, Iran

ARTICLE INFO

Article type:
Case report

Article history:
Received: 17 June 2019
Revised: 01 August 2019
Accepted: 19 August 2019

Keywords:
Complication
Electrophysiological
Iatrogenic Pulmonary Thromboembolism

ABSTRACT

Pulmonary thromboembolism (PTE) is a fatal condition that may rarely occur due to complications of coronary catheter insertion. In this case report, a 41-year-old male was presented 48 hours after radiofrequency catheter ablation (RFCA) for the management of Wolf-Parkinson-White syndrome with acute onset of dyspnea, hemoptysis, and chest pain. The physical examination revealed coarse crackles in the base of left hemithorax and laboratory tests were normal. The patient was suspicious for PTE based on clinical symptoms and the history of RFCA. Diagnosis was confirmed by computed tomography angiography of lungs. Patient symptoms improved after 3 months of treatment with warfarin.

► Please cite this paper as:

Mozdourian M, Rezaeetalab F. Pulmonary Embolism as a Complication after radiofrequency catheter ablation Study: A Case Report *J Cardiothoracic Med.* 2019; 7(4):554-556

Introduction

Acute pulmonary thromboembolism (PTE) is a fatal condition that may result in 10% mortality within the first hour from the initiation of the event (1). Mortality may increase to 30% in untreated cases (2). The main cause of mortality in acute PTE is due to the underlying causes (3). The clinical presentation of acute PTE is diverse and makes its diagnosis challenging (1). Immobilization, malignancy, recent major surgery, and orthopedic surgery are among predisposing factors for PTE, as well as dyspnea, tachycardia, and chest pain (1). One of the rare causes of PTE is coronary

catheter insertion due to the pressure injection of contrast media (4). We hereby report a case of PTE incidence due to coronary catheter insertion for treatment of Wolf-Parkinson-White (WPW) syndrome.

Case presentation

The case was a 48-year-old man with sudden occurrence of dyspnea, pleuritic chest pain, and hemoptysis who was admitted to the Pulmonology Ward of the Imam Reza Hospital, Mashhad, Iran. He had no history of medical conditions. The patient experienced episodes of palpitation in 2 years prior to the study. He was diagnosed with WPW based on the electrocardiogram (ECG). He was a

*Corresponding author: FaribaRezaeetalab, Lung Diseases Research Center, Mashhad University of Medical Sciences, Mashhad, Iran. Tel and fax: 05138431252 E-mail: Rezaeetalab@mums.ac.ir

© 2016 mums.ac.ir All rights reserved.

This is an Open Access article distributed under the terms of the Creative Commons Attribution License (<http://creativecommons.org/licenses/by/3.0>), which permits unrestricted use, distribution, and reproduction in any medium, provided the original work is properly cited.

candidate for radiofrequency catheter ablation (RFCA). Catheter ablation was performed under local anesthesia and fluoroscopy using the Biosense Webster and St Jude in the right posteroseptal area. The RFCA procedure was successful. Forty-eight hours after the RFCA the patient had sudden dyspnea, pleuritic chest pain, and non-massive hemoptysis. Moreover, the patient had no history of previous thromboembolic events, prolonged immobility, or family history for thromboembolic diseases.

In the baseline physical examination, he had stable vital signs and hemodynamic state. A coarse crackle was audible at the base of the left hemithorax in auscultation. No difference was observed in the lower extremity diameter between limbs. Laboratory tests, including complete blood count, urea, creatinine, serum sodium and potassium, prothrombin time, partial thromboplastin time, and international normalized ratio (INR) were within normal range. Intravenous heparin was administered for the patient with the diagnosis of pulmonary embolism. The patient underwent computed tomography angiography (CTA). The CTA revealed filling defect in the left inferior lobar branch of the pulmonary artery with extension to the following segments indicative of embolus (Figure 1). Other findings of CTA indicated mild pleural effusion with passive collapse in the left hemithorax and wedge shape consolidation in the anterolateral and basal segments of the inferior lobe of the left lung, which were indicative of pulmonary infarction. Lower extremity color doppler ultrasound scan was normal and the ejection fraction was 60% in echocardiography. The left ventricle size, systolic function, and the pulmonary artery pressure (PAP) at rest were normal, while a mild diastolic dysfunction was present in echocardiography. In the thrombophilia workup, the protein C and S levels, as well as anticardiolipin, antiphospholipid, and antithrombin levels were normal with no signs of mutation in prothrombin gene. Based on the sequence of the events, history of RFCA, and lack of any risk factor for pulmonary thromboembolism, the patient was diagnosed with iatrogenic thromboembolism due to the insertion of multiple venous sheath. He received

intravenous heparin for 5 days and warfarin was administered at 5 mg for 3 months to maintain INR between 2.5 and 3.5. During the follow-up, the symptoms relieved and the patient did not experience hemoptysis or dyspnea. Control chest x-ray revealed improved signs of consolidation. In addition, Control echocardiography after 3 months was normal with no signs of PAP elevation. The dimer-D was negative; therefore, medication was discontinued for the patient.

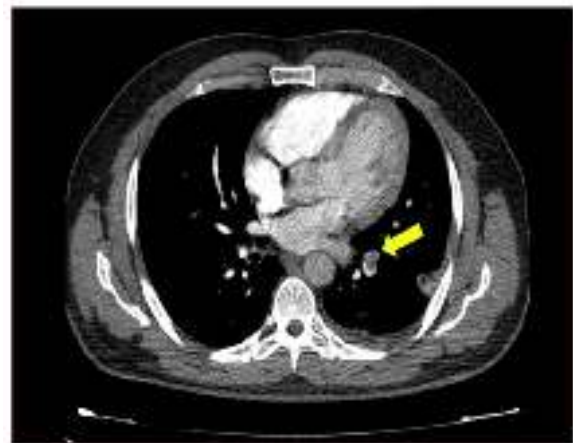


Figure 1: The CT angiography revealed filling defect in the left inferior lobar branch of the pulmonary artery

Discussion

The mechanism for PTE includes three factors of stasis, vascular endothelial damage, and hypercoagulability. Stasis can be due to prolonged immobilization following surgery, catheterization, or labor. Vascular endothelial damage can be due to tumor invasion or trauma. Hypercoagulability can also be due to conditions, including pregnancy, splenectomy, or malignancy (5). In the present case, vascular endothelial damage might be related to venous puncture, followed by PTE. The other reason for PTE, in this case, can be the chemical characteristic of the contrast agent, which might have resulted in increased coagulability and PTE (6).

As mentioned before, the PTE mortality rate is high and the most important predictors of the mortality include the time elapsed from the initiation of the event till the diagnosis and treatment (6). The PTE may be accompanied by symptoms, including chest pain, sudden onset dyspnea,

cough, tachycardia, and shock. The PTE diagnosis solely based on clinical symptoms is difficult. Suspicion of PTE should be confirmed by blood tests, chest X-ray, ECG, and echocardiography, as well as lung perfusion scintigraphy and pulmonary CTA (7).

Management of PTE is based on the extent of involvement and severity of the patients' symptoms. Primary systemic fibrinolysis is unfavorable in intermediate-risk PTE; therefore, catheter-directed techniques are considered as an option in patients with hemodynamic decompensation who have a high risk for bleeding. New oral anticoagulant agents are effective and safe alternatives to standard anticoagulation regimens (7).

Conclusion

Physicians should always consider PTE as a differential diagnosis for acute respiratory symptoms after diagnostic or interventional coronary procedures. Furthermore, all patients undergoing cardiac catheter insertion should be monitored for signs and symptoms of PTE after the procedure to prevent and timely diagnose potential complications.

Conflict of Interest

The authors declare no conflict of interest.

References

1. Nagamalesh UM, Prakash VS, Naidu KC, Sarthak S, Hegde AV, Abhinay T. Acute pulmonary thromboembolism: Epidemiology, predictors, and long-term outcome . A single center experience. *Indian Heart J.* 2017; 69:160-4.
2. Bělohávek J, Dytrych V, Linhart A. Pulmonary embolism, part I: epidemiology, risk factors and risk stratification, pathophysiology, clinical presentation, diagnosis and nonthrombotic pulmonary embolism. *Exp Clin Cardiol.* 2013; 18:129-38.
3. Carson JL, Kelley MA, Duff A, Weg JG, Fulkerson WJ, Palevsky HI, et al. The clinical course of pulmonary embolism. *N Engl J Med.* 1992; 326:1240-5.
4. Fernando SM, Munene PM, Pena E. Iatrogenic pulmonary air embolism. *CMAJ.* 2017; 189:E1069.
5. Stein PD, Beemath A, Olson RE. Trends in the incidence of pulmonary embolism and deep venous thrombosis in hospitalized patients. *Am J Cardiol.* 2005; 95:1525-6.

6. Kivrak T, Durmus E, Atas H, Sunbul M, Sari I. A rare case of acute pulmonary embolism after coronary angiography due to sand bag compression. *Int J Angiol.* 2013; 22:255-8.

7. Konstantinides SV, Barco S, Lankeit M, Meyer G. Management of pulmonary embolism: an update. *J Am Coll Cardiol.* 2016; 67:976-90.