

Localized Lymphomas presenting in the chest wall: A rare case report

Reza Bagheri^{1*}

¹ Thoracic Surgeon, Lung Diseases Research Center, Mashhad University of Medical Sciences, Mashhad, Iran.

ARTICLE INFO

Article type:
Images in Cardiothoracic Surgery

Article history:
Received: 20 Feb 2020
Revised: 30 Feb 2020
Accepted: 03 March 2020

Keywords:
CT-scan
Diagnosis
Lymphoproliferative

ABSTRACT

A 35-year-old male presented with a history of chest wall pain and swelling. It was decided to perform a CT-scan of the thorax that revealed of a rib involvement in the right hemithorax (Fig 1). We evaluated the yield of core needle biopsy in patients that the was diagnosed lymphoproliferative disorder. Investigation abdominal and pelvic CT scan and blood tests were found no other lesions. The patient underwent resection with reconstruction mesh and cement and muscle flap (Fig 2). Final Pathologic Diagnoses for Patients was reported with Lymphoma.

► Please cite this paper as:

Bagheri R. Localized Lymphomas presenting in the chest wall: A rare case report. *J Cardiothoracic Med.* 2020; 8(1):589-590

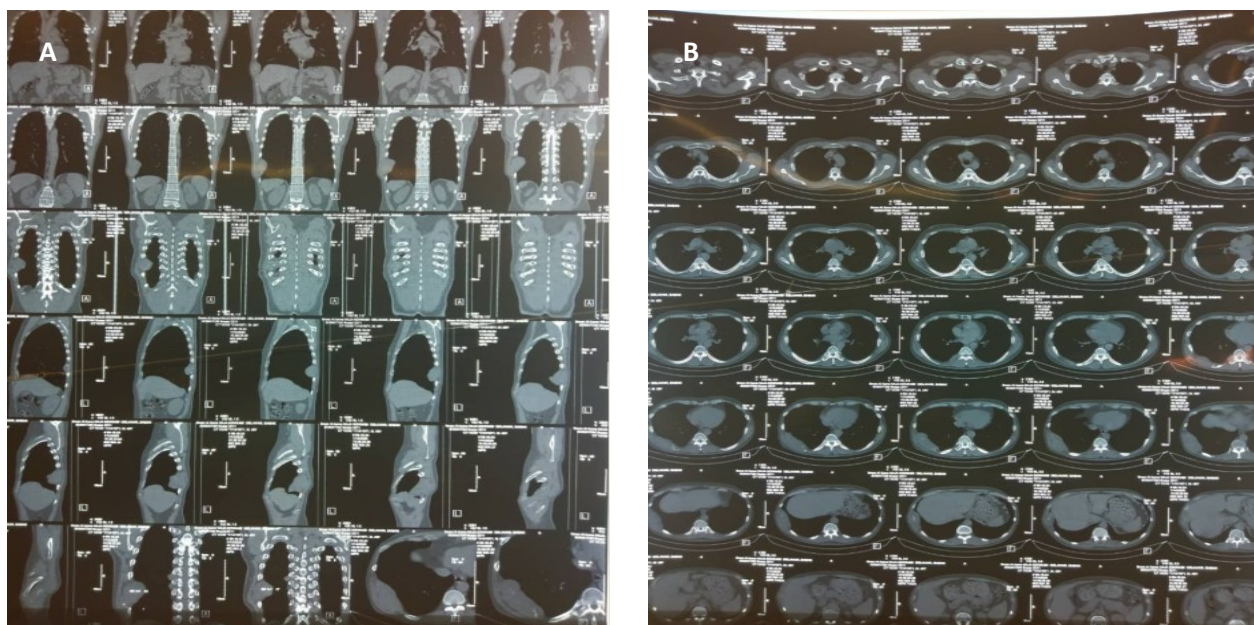


Figure 1 (A,B): Computed tomography scan rib involvement in the right hemithorax

*Corresponding author: Corresponding author: Reza Bagheri, Lung Diseases Research Center, Mashhad University of Medical Sciences, Mashhad, Iran. Tel and Fax: +985138402972; Email: Bagherir@mums.ac.ir
© 2016 mums.ac.ir All rights reserved.

This is an Open Access article distributed under the terms of the Creative Commons Attribution License (<http://creativecommons.org/licenses/by/3.0>), which permits unrestricted use, distribution, and reproduction in any medium, provided the original work is properly cited.

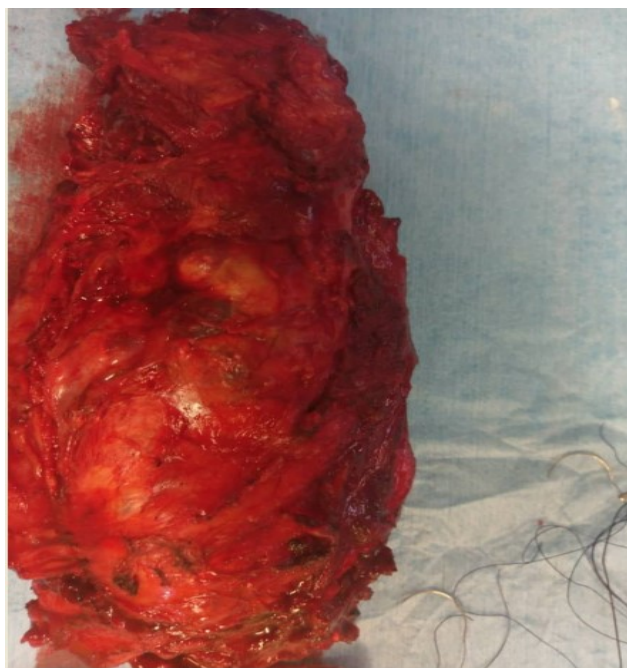


Figure 2: A macroscopic photograph showing of Lymphoma