

## Left Atrial Ball Valve Thrombus

Sumit Modi<sup>1</sup>, Aakash Joshi<sup>\*1</sup>, Mohammed Ibrahim<sup>1</sup>, Mausam Garrach<sup>1</sup>

<sup>1</sup> Departments of Cardiothoracic and Vascular Surgery, UN Mehta Institute of Cardiology and Research, India.

### ARTICLE INFO

Article type:  
Case Report

#### Article history:

Received: 15 November 2023

Revised: 25 November 2023

Accepted: 11 December 2023

#### Keywords:

Rheumatic heart disease

Mitral stenosis

Ball valve thrombus

Echocardiography

### ABSTRACT

"Ball valve thrombus" which is a spherical free-floating clot in left atrium is an often quoted, but uncommonly encountered complication in patients with severe mitral stenosis of rheumatic origin, who are in atrial fibrillation. We describe the case of a 48-year-old man with rheumatic heart disease, severe mitral stenosis, and severe aortic regurgitation. The patient presented with an episode of non-exertional syncope resulting in CVA 1 month back and breathlessness on exertion of 6 months duration and was in normal sinus rhythm. Echocardiography facilitated ante-mortem diagnosis and prompt institution of surgery was lifesaving.

► Modi, S., Joshi, A., Ibrahim, M., Garrach, M. Left Atrial Ball Valve Thrombus. *J Cardiothorac Med.* 2023; 11(3): 1223-1225.  
Doi: 10.22038/jctm.2023.76019.1433

### Case Description

#### Introduction

A spherical free-floating clot in left atrium is un- common, mostly occurring in patients with severe mitral stenosis of rheumatic origin. Such a clot is appropriately named as "ball valve thrombus". This entity, an often-quoted complication of mitral stenosis, is extremely rare (1). Ball valve thrombus has potential life-t threatening consequences if not treated early. We report the occurrence of this rare complication in a man with mitral stenosis and severe aortic regurgitation due to rheumatic heart disease.

A 48-year-old man with body mass index of 28kg/mt<sup>2</sup>, who was known to have rheumatic heart disease, presented with an episode of non-exertional and non postural syncope and CVA, and breathlessness on exertion of 6 months duration. On general physical examination he was conscious, alert. There was no pallor, cyanosis or dependent oedema. The jugular venous pulse was not raised; pulse was 76 beats/min, regular; blood pressure was 120/80 mm Hg in the right arm in supine position. Cardiovascular system examination revealed features suggestive of

\*Corresponding Author: Dr Aakash Joshi, Senior Resident, UN Mehta Institute of Cardiology and Research, India. Tel: + 9916038565 ; e-mail: draakashjoshi@gmail.com .

© 2016 mums.ac.ir All rights reserved

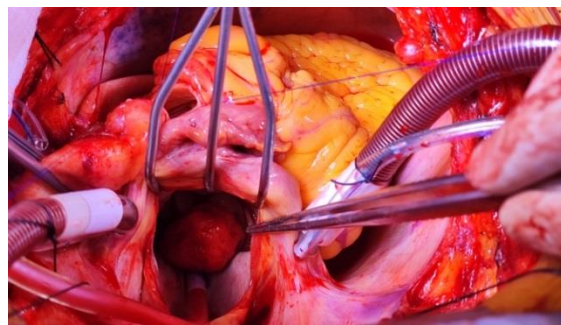
This is an Open Access article distributed under the terms of the Creative Commons Attribution License (<http://creativecommons.org/licenses/by/3.0>), which permits unrestricted use, distribution, and reproduction in any medium, provided the original work is properly cited.

severe mitral stenosis and severe aortic regurgitation. His chest radiograph revealed left atrial enlargement and mild pulmonary venous congestion. All his peripheral pulses were felt and he had no neurological deficits. His electrocardiogram (ECG) revealed sinus rhythm with left atrial overload pattern. His echocardiogram confirmed rheumatic heart disease with severe mitral stenosis, severe aortic regurgitation, and moderate pulmonary arterial hypertension (PAH) with RVSP of 46mmhg. In addition, a spherical large smooth walled free-floating thrombus, measuring 22×30 mm was observed in the left atrium appendage, intermittently albeit transiently occluding the left ventricular inflow. The patient underwent open heart surgery, removal of clot (Figure 1), mitral and aortic valve replacement. At 2 months follow-up post-surgery, the patient is doing well and is asymptomatic with echo mentioning no valvular leak and no residual clots.

## Discussion

Ball-valve thrombus, a free-floating thrombus within the left atrium is a rare entity. Till date, less than 60 cases have been reported till the 1980's (2-4). In most of the patients presenting with a ball valve thrombus, severe mitral stenosis of rheumatic origin has been the most common pre-disposing condition. Our patient had severe mitral stenosis and moderately severe aortic stenosis of rheumatic origin. Infrequently, ball valve thrombus has been described in patients with mechanical mitral prosthetic valve (5), bio-prosthetic valve (6), in isolated severe aortic stenosis (7), and in patients with no valvular heart disease (8). The reason for typical spherical shape could be because of fresh clot being layered out concentrically as it spins around the atrium (9). The diagnosis of a free ball valve thrombus is based on two criteria: the thrombus must be larger than the orifice of the valve, and it must have a smooth surface with no signs of attachment to the atrial wall (10). Both the criteria were satisfied in our patient.

In patients with rheumatic mitral stenosis who develop a ball valve thrombus as a



**Figure 1.** Gross specimen photograph showing a spherical clot that was found to be free floating in the left atrium at the time of surgery.

complication, atrial fibrillation is often present (2-4). In contrast, our patient was in normal sinus rhythm, suggesting that ball valve thrombus can rarely develop in patients with normal sinus rhythm also. Clinically ball valve thrombus can produce symptoms of heart failure or embolic stroke, peripheral embolism, or sudden death (9). The risk of systolic embolism in patients with left atrial thrombus is high and estimated to be around 10.4% per year (11), suggesting that the stenotic mitral valve orifice does not effectively guard against thromboembolism. It may also happen that ball valve thrombus may embolize silently causing either embolic stroke or peripheral embolism (12) or incidentally embolize during surgery causing management problems (13).

At bedside, the diagnosis may be suspected only if there is high degree of suspicion and requires assessment of the influence of change of posture on symptoms and hemodynamic parameters. Before the era of echocardiography, the diagnosis was usually made postmortem. With the advent of echocardiography, ball valve thrombus is being diagnosed more frequently (2,14). Oral anticoagulation is usually avoided in these patients as this can result in fragmentation of the thrombus and embolization. Urgent and prompt surgery as was done in our patient can be lifesaving.

## References

1. Gillmer, D. & Campanella C. Echocardiographic diagnosis of left atrial ball-valve thrombus-a case report. South african medical journal. 1984 Apr 1;65(16):662.

2. Dent RG, Dick JP, Cory-Pearce R. Left atrial ball valve thrombus. Treatable cause of clinical deterioration in a patient with mitral stenosis. *British Heart Journal*. 1983 Apr;49(4):400.
3. Abramson JL. Ball thrombi of the heart. *Ann. Clin. Med.*. 1924 Oct;3:327.
4. Donaldson RM, Ballester M, Olsen E. Diagnosis of atrial thrombi by ultrasound. *Thorax*. 1982 Jul;37(7):507.
5. Mikell FL, Asinger RW, Rourke T, Hodges M, Sharma BI, Francis GS. Two-dimensional echocardiographic demonstration of left atrial thrombi in patients with prosthetic mitral valves. *Circulation*. 1979 Nov;60(5):1183-90.
6. Alam M, Jafri SM. Ball-valve thrombus obstructing a bioprosthetic mitral valve. *Chest*. 1993 May 1;103(5):1599-600.
7. Davutoglu V, Soydinc S, Celkan A, Kucukdurmaz Z. Left ventricular free-floating ball thrombus complicating aortic valve stenosis. *Journal of Heart Valve Disease*. 2004 Mar 1;13(2):197-9.
8. Ohkado A, Nakajima S, Inoue K, Sakata M, Wakita N, Ito K. Free-floating left atrial ball thrombus without mitral valve disease. *The Japanese Journal of Thoracic and Cardiovascular Surgery*. 2005 Jan;53:52-4.
9. Schechter DC. Left atrial ball-valve thrombus. *New York State Journal of Medicine*. 1982 Dec 1;82(13):1831-8.
10. Blanche C, Chaux A, Kass RM, Helfenstein J, Sugarman G. Free-floating ball thrombus in the left atrium after mitral valve replacement: successful surgical management. *The Annals of thoracic surgery*. 1985 Jun 1;39(6):566-8.
11. Leung DY, Davidson PM, Cranney GB, Walsh WF. Thromboembolic risks of left atrial thrombus detected by transesophageal echocardiogram. *The American journal of cardiology*. 1997 Mar 1;79(5):626-9.
12. Cecconi M, Manfrin M, Moraca A, Cacitti V, Molini E, Ferrini L, et al. Silent embolism of a large pedunculated left atrial thrombus. *Italian Heart Journal: Official Journal of the Italian Federation of Cardiology*. 2002 Mar 1;3(3):199-201.
13. Paul B, Sachdeva A, Sharma V, Kumar V, Shrivastav S, Omar AK. Thrombotic occlusion of bilateral popliteal arteries by ball valve thrombus in left atrium. *J Assoc Physicians India*. 2009 Jul 1;57:531.
14. Sunagawa K, Orita Y, Tanaka S, Kikuchi Y, Nakamura M, Hirata T. Left atrial ball thrombus diagnosed by two-dimensional echocardiography. *American Heart Journal*. 1980 Jul 1;100(1):89-94.