

## Computed Tomography Imaging findings in Chemical Warfare Victims with pulmonary Complications

Majid Mirsadraee<sup>\*</sup>, Saeed Naghibi<sup>2</sup>, Amir Hosein Hashemi Attar<sup>2</sup>, Zahra Salehinezhad<sup>3</sup>, Saeed Mirsadraee<sup>4</sup>

<sup>1</sup> Pulmonologist, Medical school-Islamic Azad University, Mashhad Branch

<sup>2</sup> Radiologist, Medical school- Islamic Azad University, Mashhad Branch

<sup>3</sup> General Practitioner, Zakaria Research Center, Medical School, Islamic Azad University, Mashhad Branch

<sup>4</sup> Senior Lecturer in Radiology, University of Edinburgh, UK.

### ARTICLE INFO

Article type:  
Original article

Article history:  
Received: 1 Dec 2013  
Revised: 14 Jan 2013  
Accepted: 22 Jan 2013

Keywords:  
Chemical warfare victims  
High-Resolution Computed Tomography (HRCT)  
Sulfur mustard  
Air trapping  
Bronchiolitis Obliterans

### ABSTRACT

**Introduction:** Data on imaging findings in pulmonary complications of chemical agents is scarce. The current study aimed to evaluate radiological findings of late onset pulmonary complications in chemical warfare victims (CWV) and to guide pulmonologists in diagnosis of these subjects.

**Materials and Methods:** Ninety-three male CWV were enrolled in this prospective study, 20-25 years (mean=23) after exposure. Demographic and clinical data were recorded. High resolution computed Tomography (HRCT) of the lung was performed during inspiration and expiration and was double reported blindly by two radiologists. Final diagnosis was made according to HRCT findings. The HRCT findings, final diagnosis, and distribution of the abnormalities were compared between subjects whom had been exposed to more complex chemical agents used during the second half of the war and simpler agents during the first half.

**Results:** The most frequent HRCT findings were air trapping (56.7%) and mosaic attenuation (35.1%). The distribution of abnormalities was mostly local (79.4%) and bilateral (73%) especially in lower regions (61.3%). The diagnosed respiratory diseases included bronchiolitis obliterans (43%), chronic obstructive pulmonary disease (COPD) (27.9%), asthma (23.6%), bronchiectasis (13.9%) and interstitial lung disease (ILD) (9.6%). Frequency of subjects involved in the second half of the period of war was more than the first period ( $P$ -value < 0.05) but the HRCT findings were similar.

**Conclusions:** Bronchiolitis obliterans with picture of focal bilateral air trapping was the most common finding in CWV but asthma appeared to have become a new problem in these subjects.

### Introduction

Over 20 years ago, during Iran- Iraq war (1980-1988), many people were exposed to chemical agents. Many of the chemical warfare victims (CWV) were reported to present with pulmonary conditions such as fibrosis, chronic obstructive pulmonary disease (COPD), and

bronchiectasis (1-4). Previous studies reported radiological and histological diagnosis of bronchiolitis obliterans (BO) in this cohort of patients(1,2). More recent studies have reported later presentation of these patients with airway hyper responsiveness and clinical response to inhaled corticosteroids indicating late onset asthma (resistance subtype with or without remodeling)(3).

\* Corresponding author: Majid Mirsadraee, No: 80, 15th Kosar, Kosar Ave, Vakilabad Blvd., Mashhad, Iran, Post code: 9178673799, Tel: 0511-8416694, Mobile : 09151115860, Fax: 0511-8816965, E-mail: majidmirsadraee@yahoo.com, majidmirsadraee@mshdiau.ac.ir  
© 2013 mums.ac.ir All rights reserved.

This is an Open Access article distributed under the terms of the Creative Commons Attribution License (<http://creativecommons.org/licenses/by/3.0>), which permits unrestricted use, distribution, and reproduction in any medium, provided the original work is properly cited.

Diagnosis of chemical agents related to lung injury is usually made following a confirmed history of chemical exposure, and relevant post-exposure clinical disorders such as the blistering skin lesions and/or a history of acute pneumonitis(2). Radiological investigations may be used to evaluate the pulmonary disease and estimate the severity. In addition, in illusive subjects they can confirm the pulmonary disorders such as BO that is relatively rare in community. In the current practice, diagnosis of BO and positive history of exposure mentioned above were the most convincing method to diagnose chemical warfare pulmonary disease. Radiological investigations may however be unremarkable especially in patients with chemical asthma.

The current study aimed to evaluate CT findings of the late pulmonary complications of CWV and the potential role of CT in differentiating CWV from routine lung disease.

## Materials and Methods

Ninety-three male patients 20-25 years (mean=23) after exposure to chemical agents referred for the investigation and treatment of their pulmonary disease by the Janbazan Medical Institute (a government funded organization that is responsible for the care of chemical war victims in Iran). All patients with a confirmed history of exposure to skin blister agents such as sulfur mustard during the war and respiratory symptoms such as dyspnea and/or cough were enrolled in the study. Subjects with history of smoking, recent pulmonary infection, exposure to other toxins such as birds/toxic drugs, and heart disease were excluded.

The Azad University Ethics Committee approved the study. All subjects were informed and consented. Patients completed a questionnaire to collect patients' demographics, current and previous clinical complaints, and history of exposure to chemical agents during the war and other potential occupational and environmental pulmonary toxins. Subjects with a history of smoking, recent pulmonary infection and heart disease were excluded from the study.

This is believed that the type of chemical agents used might have changed during the 8-year war. To study the potential effects, patients were divided into two groups: 36 patients from the first 4 years of the war and 57 from the second 4 years period.

### CT Techniques and radiological interpretation:

Spiral CT was performed on a High Philips Mx8000 scanner (Philips Medical Systems, Best, the Netherlands). Images were obtained by means of 120 kVp and 440 mAs at end-expiratory and inspiratory phases. High-spatial-resolution algorithm reconstruction was performed at 1 mm collimation. Images were reviewed using lung pa-

renchymal window level (level -600 to -700 H; window width, 1000-2000 H) and mediastinal soft-tissue window level (level, 30-50 H; width, 350-500 H).

Two radiologists independently had a cross sectional review of studies without access to clinical history. Patients were divided into two groups depending on their onset of chemical exposure during the war (it is believed that later in the 8-year war, victims might have been exposed to more complex and fatal chemical agents). The first group was exposed during the first 4 years of war, and the second group during the second 4 years.

Based on imaging findings, patients were classified into five diagnostic groups: 1-patients with bronchiolitis with or without bronchiectasis (eg. bronchiolitis obliterans, asthma), emphysema, and pulmonary fibrosis. Specific HRCT signs of bronchiolitis included mosaic attenuation, expiratory phase air trapping, centrilobular nodules, bronchial wall thickening, tree-in-buds, pulmonary nodules, and ground glass changes; 2- Emphysema: Area of low attenuation; 3- Bronchiectasis: Signet ring sign; 4- Asthma: Normal CT scan with or without air trapping; 5- IPF (Idiopathic pulmonary fibrosis): fine reticular parenchymal changes, sub-pleural honeycombing.

### Statistical analysis:

Sample size was adopted based on previous data (2) on the frequency of pulmonary disease in Iran- Iraq war veterans with 0.05 alpha errors and 80% potency. Descriptive results were generated from demographic data, radiological findings and final diagnosis. Student's t-test and chi-squared methods were employed to compare the two groups. The significance level was set at  $P < 0.05$ .

## Results

Ninety-three CWV (all male) were enrolled in this study. Mean of age was  $44 \pm 6.9$  years (35-67). All except one had only one episode exposure to chemical agents. Time from exposure to the time of CT ranged from 20 to 25 years (mean=23). The most frequent respiratory complaints were cough (95.6%) and dyspnea (93.5%).

### HRCT findings

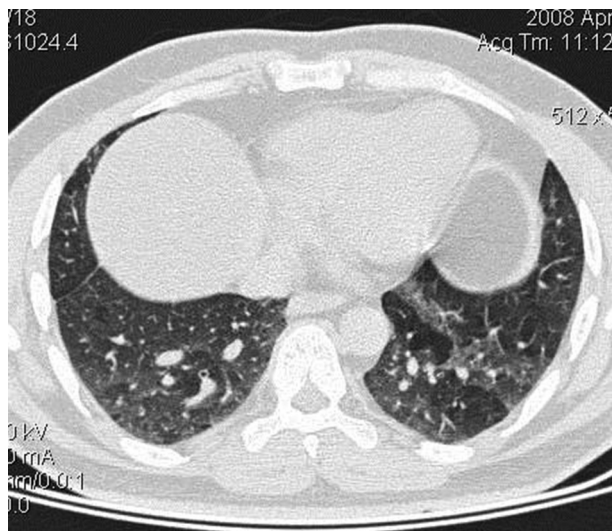
Table 1 summarizes the CT findings in CWV patients with pulmonary diseases. The most common findings included air trapping (59%), mosaic attenuation (36%) and ground glass changes (21.5%) (Figure 1). These changes were diffuse in most cases. Diffuse nodular changes were present in 18% of cases. Over 15% had evidence of bronchial wall thickening and dilatation (Figure 2,3). Multifocal pulmonary fibrosis and diffuse interstitial pattern were present in 13% of cases (Figure 4). Tree-in-bud and nodular lesions were present in 4% and 17% respectively (Table 1) (Figure 2).

**Table 1.** Frequency of most important radiological findings observed in lung CT scan of CWV and comparison of frequency of localized and diffuse lesion (percent of frequency from total subjects)

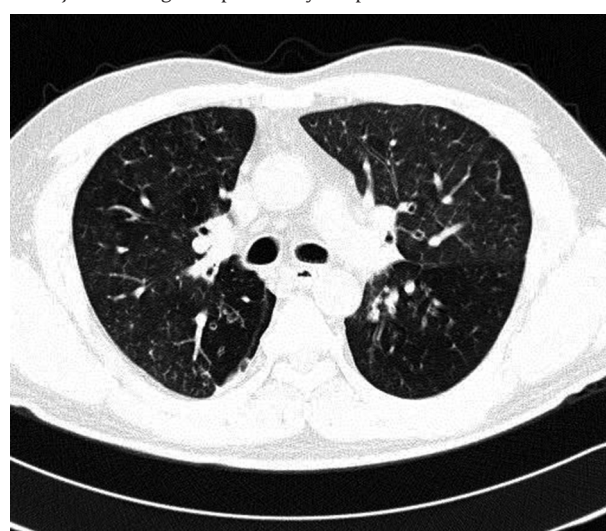
	Localized	Diffuse	X <sup>2</sup>	P value
Air trapping	3 (3.2%)	52 (56%)	31.4	0.0001
Mosaic perfusion	0	34 (36%)	19	0.0001
Ground glass	0	20 (21.5%)	9.3	0.001
Nodular pattern	0	17 (18%)	7.6	0.003
Tree in bud	0	4 (4.3 %)	1.5	0.27
Bronchial wall thickening	0	9 (10%)	3.6	0.05
Bronchial dilatation	0	7 (7.5%)	2.7	0.1
Fibrosis	2 (2.2 %)	10 (11 %)	0.7	0.31
Signet ring	1 (1.1 %)	14 (15 %)	3.7	0.045

P value evaluated by Fisher exact test

The least common radiological findings were consolidation (n=1, 1%), cavity (n=2, 2%), honeycombing (n=1, 1%) and pleural thickening (n=2, 2%). When observed, these changes were bilateral. Lower lobes were the most involved (58%). Involvement of right middle lobe was observed in 23 subjects (25%), and upper lobe was the least involved (n=3, 3%).

**Figure 1.** Bilateral lower lung air trapping and mosaic perfusion in a chemical warfare victim

Comparison of the frequency of HRCT findings from the two groups of patients from the first 4 years (39% of patients) and those of the second 4 years of war showed no significant differences except higher frequency of nodular pattern in patients from the second half (15% vs. 3%, P=0.0038) (Figure 5). The localization of lesions was not statistically related to the duration of disease.

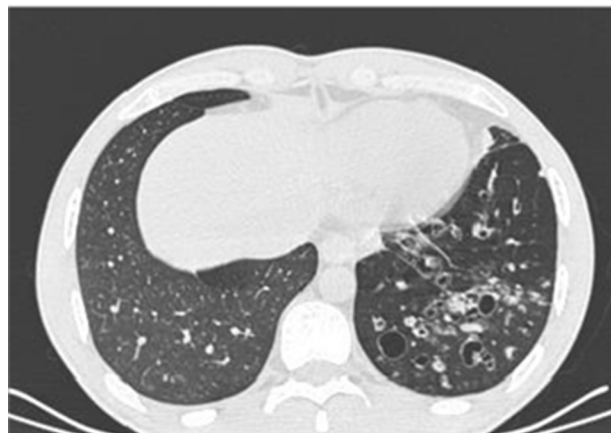
**Figure 2.** Bronchial wall thickness, air trapping and tree in bud pattern in subject suffering from pulmonary complication of chemical warfare.**Table 2.** Comparison of specific pulmonary disease in CWV between two groups of first half of Iran-Iraq war period and second half.

	First half	Second half	P value
Bronchiolitis obliterans (42)	18 (43%)	24 (57%)	0.0001
Asthma (24)	9 (37.5%)	15 (62.5%)	0.02
Bronchiectasis (9)	3 (33.3%)	6 (66.7%)	0.05
COPD (12)	7 (58%)	5 (42%)	0.02
ILD (6)	0	6 (100%)	0.0004
Total	37 (39%)	56 (41%)	

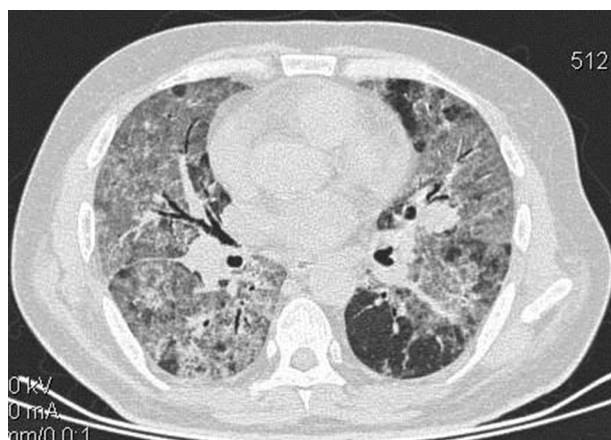
COPD= Chronic obstructive pulmonary disease, ILD= Interstitial lung disease



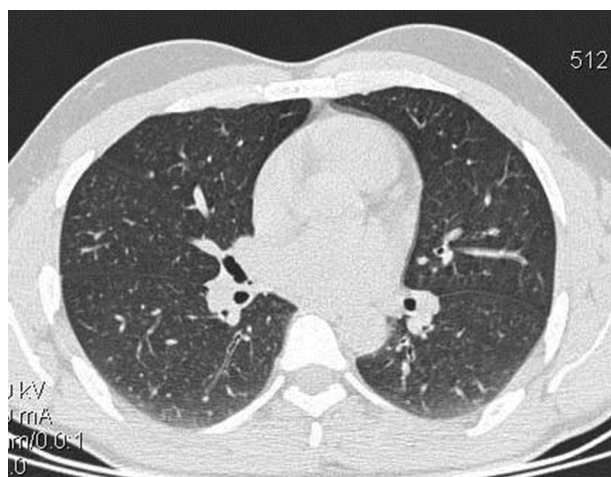**Figure 3.** Unilateral bronchial wall thickness and dilation in subject suffering from pulmonary complication of chemical warfare.



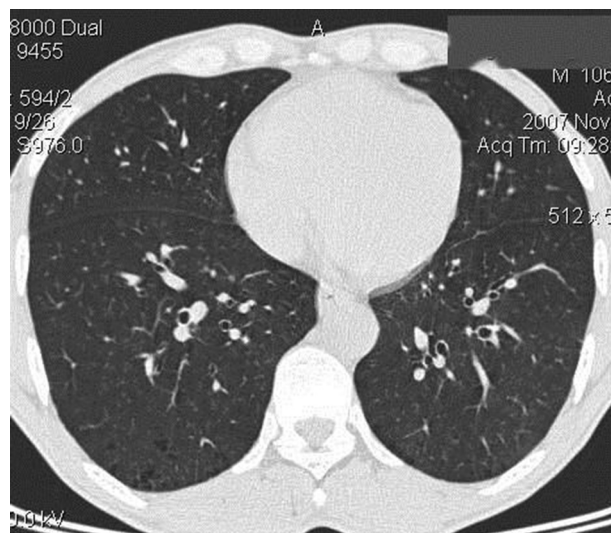
**Figure 4.** Diffuse interstitial pattern and fibrosis in subject suffering from pulmonary complication of chemical warfare



**Figure 5.** Nodular pattern in chemical warfare victim suffering from bronchiolitis obliterans



**Figure 6.** Localized peripheral low attenuation suggestive of emphysema in subject suffering from pulmonary complication of chemical warfare.



### Specific radiological diagnosis

Frequency of specific radiological diagnosis is summarized in Table 2. All specific diseases were significantly more frequent in CWV from the second half of war, except COPD that was more frequent in CWV from the first half of war.

Overall interpretation of the radiological findings by the two radiologists showed that bronchiolitis was the most common pathology observed in over 70% of the patients (Figure 2,5). Over 60% of these patients had more complex combination of findings such as air trapping with nodular pattern in 15 (37%), tree-in-bud in 4 (9.5%), and bronchial wall thickening in 7 (17%) (Figure 2). These patients were classified as BO (44% of the total). Patients with relevant pulmonary symptoms and normal HRCT or only mild air trapping (n=24; 26%) were categorized as asthma.

Bronchiectasis was the diagnosis in 9 patients (10%). Twelve patients (13%) had simple emphysema (Figure 6). Lung fibrosis was the radiological diagnosis in 6 subjects (6.5%) (Table 2).

### Discussion

Inhalation of toxic chemical fumes including those used during wars may result in debilitating pulmonary complications. The diagnosis and treatment of pulmonary disorders in this group of patients may be challenging. This study aimed at HRCT characterization of late onset pulmonary complication of inhaled chemical toxins during Iran-Iraq war.

Previous studies had shown that amongst survivors of mustard gas toxicity in the Iran-Iraq war, nearly all victims suffered from respiratory injuries whilst the fatality was 3-4% (4,5). Acute exposure to mustard gas results in dose dependent inflammatory changes in surface organs such

as skin, eye and respiratory tract and especially respiratory mucosal inflammation and necrosis (1,6). Patients may then suffer from recurrent pulmonary infections (7). Medium and long-term follow-up studies demonstrated chronic respiratory disorders such as bronchiolitis, bronchiectasis and fibrosis.

During the 8-year conflict, although not clearly documented, it is believed that later in the war, chemical weapons made of a mixture of two or three chemical agents (nerve, blister and cyanide) (1) were used. Although these mixtures were more lethal, survivors continued to suffer from respiratory complications of the blistering agents, mainly sulfur mustard. The current study showed that the HRCT findings were mostly similar in patients who were injured earlier or later in the war.

The most common HRCT findings were air trapping, mosaic attenuation and ground glass opacities. In a similar study of 50 CWV, air trapping (76%), bronchiectasis (74%), mosaic parenchymal attenuation (72%), major airway dilatation (66%) were the most frequent HRCT findings (5). These findings may indicate that the main pathology in these patients is small airway centered and in particular bronchiolitis (eg. BO and asthma). Other studies reported involvement of large airways. Ghanei et al. detected tracheobronchomalacia in 4.3% of CWV patients (8). Although the diagnosis of bronchiolitis is non-specific, pulmonologist may still find it useful to plan management and estimate prognosis. Previous studies suggested that HRCT might be useful in detection of subclinical cases. In a study of 200 asymptomatic CWV patients, HRCT detected air trapping, septal thickening and bronchiectasis in 61% of subjects (9). However, the clinical value of investigating asymptomatic patients by CT is questionable and the risk of radiation may not be justified. Although chest x-ray findings in these patients is reported to be usually non-specific (10), other studies found it useful in up to 13% of cases (11). The use of chest x-ray may be justified as a screening tool in asymptomatic patients to exclude significant pathologies.

In the current study, 44% of patients were diagnosed with BO and 26% with asthma. In 1997, a clinico-radiological study of 197 patients with a history of single, heavy exposure to sulfur mustard gas reported that 10 years following exposure, 59% of patients were diagnosed with chronic bronchitis and 11% with asthma (3). Although absolute comparison of the two studies is not possible due to methodological differences, both studies show a high incidence of small airway diseases in this group of patients 10 and 20 years following the exposure.

Bronchiectasis was observed in 9 (10%) subjects. In a previous cross-sectional study, bronchiectasis was reported in 26% of cases (4). Hosseini et al also reported 16 cases of bronchiectasis proven by bronchography or HRCT out of 61 cases of CWV (24%). Both diffuse and focal forms of

bronchiectasis (more frequently in the lower lobes) were encountered in the current study ( ). Although compared to previous studies, the exact reason for lower rates of bronchiectasis in the current study is uncertain, differences in patients' characteristics (eg. the dose of chemicals patients were exposed to), or differences in methods of studies may be the reason.

Pulmonary fibrosis is consistently reported in these groups of patients with a frequency of 7.5-12% of CWV (3,4) and 6% in the current study. The frequency of COPD was marginally less (13%) in comparison to a previous study by Bagheri et al that reported emphysema in 24% (2).

In conclusion, bronchiolitis obliterans appears to be consistently the most frequent pulmonary complication of chemical agents 20 years following the onset of exposure. Other forms of bronchiolitis such as asthma are common.

## Acknowledgement

The authors would like to thank vice chancellery of Research of Islamic Azad University, Mashhad Branch for financial support.

**Conflict of interest:** The authors declare no conflict of interest.

## References

1. Ghanei M, Mokhtari M, Mohammad MM, Aslani J. Bronchiolitis obliterans following exposure to sulfur mustard: chest high resolution computed tomography. *Eur J. Radiol* 2004; 52:164-9.
2. Beheshti J, Mark EJ, Akbaei HM, Aslani J, Ghanei M. Mustard lung secrets: long term clinicopathological study following mustard gas exposure. *Pathol Res Pract* 2006; 202:739-44.
3. Mirsadraee M, Attaran D, Boskabbady MH, Towhidi M; Airway hyper responsiveness in chemical warfare victims, *Respiration* 2005;72:523-528.
4. Balali-Mood M, Hefazi M, Mahmoudi M, Jalali E, Attaran D, Maleki M, et al. Long-term complications of sulfur mustard poisoning in severely intoxicated Iranian veterans. *Fundam. Clin. Pharmacol.* 2005; 19:713-721.
5. Fouyn TH, Lison D, Wouters M, Maynard RL, Meredith TJ, Marrs TC, Vale JA, Willems JL, De Leenheer AP, De Bisschop HC. Management of chemical warfare injuries. *Lancet* 1991; 337:121-122.
6. Freitage, L., N. Firusian, G. Stamatis & D. Grescheuchua: The role of bronchoscopy in pulmonary complications due to mustard gas inhalation. *Chest* 1991; 100:1436-1441.
7. Papirmeister B, Feister A J, Robinson S I, Ford RD. Medical Defense Against Mustard Gas: Toxic Mechanisms and Pharmacological Implications. Boca Raton: CRC Press, pp. 43-78.
8. Ghanei M, Moqadam FA, Mohammad MM, Aslani J. Tracheobronchomalacia and air trapping after mustard gas exposure. *Am J Respir Crit Care Med.* 2006 1;173:253-4.
9. Ghanei M, Fathi H, Mohammad MM, Aslani J, Nematizadeh F. Long-term respiratory disorders of claimers with subclinical exposure to chemical warfare agents. *Inhal Toxicol.* 2004;16:491-5.
10. Mansoor Ghanaei F, Alizadeh A. Chest X-ray findings in Guilanian chemical warfare victims. *Journal of Babol university of medical sciences* 1999;3: 13-8
11. Bijani Kh, Heidari B. Long-term effects of exposure to chemical warfare on the respiratory system of war victims. *Hakim Research Journal* 1382;1(6): 34-29
12. Hosseini K, Bagheri MH, Alavi S, Mostafavi H. Development of bronchiectasis; a late sequela of Mustard gas exposure. *Iranian Journal Of Medical Sciences* 1998;4-3(23): 81-84.