

## Clinical and Para-Clinical Presentations of Endobronchial Tuberculosis

Seyyed Hosein Ahmadi Hoseini<sup>1</sup>, Elham Ghalenavi<sup>2\*</sup>, Mahnaz Amini<sup>3</sup>

<sup>1</sup> Pulmonologist, Lung Disease Research Center, Faculty of Medical Sciences, Mashhad University of Medical Sciences, Mashhad, Iran

<sup>2</sup> Internist, Department of Internal Medicine, Faculty of Medical Sciences, Mashhad University of Medical Sciences, Mashhad, Iran

<sup>3</sup> Pulmonologist, Lung Disease Research Center, Faculty of Medical Sciences, Mashhad University of Medical Sciences, Mashhad, Iran

### ARTICLE INFO

Article type:  
Original Article

Article history:  
Received: 15 Apr 2015  
Revised: 18 Jun 2015  
Accepted: 15 Oct 2015

Keywords:  
Bronchoscopy  
Endobronchial Tuberculosis  
Pulmonary Tuberculosis

### ABSTRACT

**Introduction:** Tuberculosis (TB), with different types of respiratory tract involvements, has a high rate of mortality all around the world. Endobronchial involvement, which is a slightly common tuberculous infection, requires special attention due to its severe complications such as bronchostenosis. Aim of study of this study was describes, one type of pulmonary tuberculosis with less diagnosed and delayed treatment. High suspicious needs to diagnose and may be need bronchoscopy for confirmed the diagnosis. It can be associated with sever complication and early diagnosis and treatment are necessary for prevention of adverse effect.

**Materials and Methods:** This retrospective study was conducted in a teaching hospital during 2005-2010. Patients diagnosed with endobronchial tuberculosis through bronchoscopic biopsy were included in the study. Diagnosis was confirmed by observation of caseous necrosis, bronchial lavage fluid or positive acid-fast staining in tissue samples obtained through bronchial biopsy. Moreover, demographic information, endobronchial view, lab tests, as well as clinical and radiographic findings were reviewed and evaluated retrospectively.

**Results:** A total of 20 cases were confirmed with endobronchial tuberculosis, 75% of whom were female with the mean age of 60 years. The results showed that the most common clinical symptom was cough (80%), the most common finding in the chest X-ray was consolidation (75%), and the most common bronchoscopic feature was anthracosis (55%).

**Conclusion:** TB is still a major concern, particularly in the developing countries. Thus, in order for early diagnosis and prevention of this disease, we need to pay meticulous attention to its clinical manifestations and bronchoscopic features.

► Please cite this paper as:

Ahmadi Hoseini SH, Ghalenavi E, Amini M. Clinical and Para-Clinical Presentations of Endobronchial Tuberculosis. J Cardiothorac Med. 2015; 3(4):371-374.

### Introduction

Tuberculosis (TB) is still considered as one of the most lethal contagious diseases worldwide. Due to early diagnosis and treatment of this disease during 2000-2013, a global decrease in the rate of TB mortality, prevalence and incidence has been observed (by 45%, 41% and 1.5%, respectively). Yet, its mortality rate is

unacceptably high indicating the need for an accelerated approach to reach the target rate of 50% decrease till 2015.

In general, 3.5% of all the TB cases are of the multidrug-resistant type, which accounts for 1.8 million mortalities worldwide. These findings accentuate the necessity of developing more

\*Corresponding author: Elham Ghalenavi, Department of Internal Medicine, Faculty of Medical Sciences, Mashhad University of Medical Sciences, Mashhad, Iran. Tel: +985138598818; Fax: +985138598818; E-mail: ghalenavie@mums.ac.ir

© 2015 *mums.ac.ir* All rights reserved.

This is an Open Access article distributed under the terms of the Creative Commons Attribution License (<http://creativecommons.org/licenses/by/3.0>), which permits unrestricted use, distribution, and reproduction in any medium, provided the original work is properly cited.

accurate and effective diagnostic and therapeutic strategies (1). In 2013, world health organization (WHO) reported 24,000 cases of TB prevalence, 16000 cases of TB incidence, and 78 cases of TB mortality in Iran. Today, delayed diagnosis of TB is one of the greatest problems regarding this disease (2), which pinpoints the urgent need for attention and training programs (3).

Endobronchial tuberculosis (EBTB) is a less commonly known type of pulmonary TB. Diagnosis of pulmonary tuberculosis is confirmed by positive sputum smear or culture for acid-fast bacilli (AFB), Fiberoptic bronchoscopy with bronchoalveolar lavage and transbronchial biopsy can be used for diagnosis of pulmonary tuberculosis with negative sputum smears (4).

This study aims to evaluate the clinical and para-clinical features of EBTB in a population at a high risk of tuberculosis.

## Materials and Methods

In this study, medical records of patients with pulmonary disease, available in a tertiary referral center, were gathered and evaluated retrospectively. Among the patients who had undergone bronchoscopy during 2002-2006, those diagnosed with endobronchial tuberculosis entered the study. The diagnosis was confirmed through observation of granuloma with caseous necrosis in the tissue sample obtained by bronchoscopy, a positive acid-fast staining test tissue sample or a bronchial lavage positive for acid-fast bacilli (AFB).

The included patients had negative sputum smears for AFB. Demographic information, clinical and radiographic findings, laboratory tests and endobronchial view were studied in the medical records. The bronchoscopic findings were categorized based on Chung's classification.

## Results

Among the 784 patients who had undergone bronchoscopy, 20 cases were confirmed with endobronchial tuberculosis, of whom 75% were female with the mean age of 60 years. The patients' age distribution pattern is demonstrated in Table 1 and the frequency of various symptoms of the studied patients is presented in Table 2.

The results showed no bronchial preference involvement pattern, while the upper and lower lobe bronchi on both sides were involved. Their involvement pattern was defined based on Chung's classification, which was introduced in 2000. Anthracosis with incidence rate of 55%, was the most common finding, followed by caseous necrosis with the rate of 30%. Moreover, edematous-hyperemic and tumor-

like vegetation were both recorded in 25% of the cases, and fibrostenosis was observed in 20% of the cases, while ulcerative and nonspecific bronchitic features were each recorded in only one patient (5%) (Figure 1). The bronchoscopic examinations did not reveal granular pattern in any of the studied cases. The bronchoscopic features of the studied cases are summarized in Table 3.

The laboratory studies included the patients' leukocyte white blood cell (WBC) count through complete blood count and erythrocyte sedimentation rate (ESR). Among the 11 patients whose WBC count was determined, leukocytosis was observed in only one patient ( $11.7 \times 10^9/\text{lit}$ ). In the other cases WBC count was in the normal range, varying from 4 to  $10.2 \times 10^9/\text{lit}$ .

**Table 1.** Age distribution of patients with endobronchial tuberculosis

Age (yrs)	Number	Frequency Percentage
Under 20	2	10
21-40	2	10
41-60	3	15
61-80	12	60
Over 80	0	0
Unknown	1	5
Total	20	100

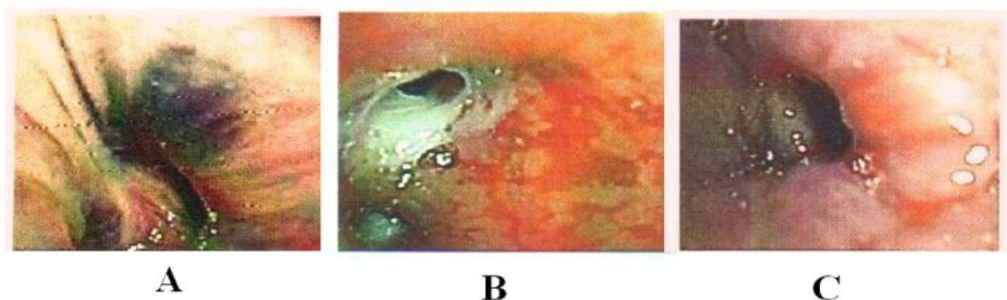
**Table 2.** The symptoms of the studied patients with endobronchial tuberculosis

Symptoms	Number	Percentage
Cough	16	80
Dyspnea	4	20
Fever	5	25
Sweating	5	25
Decreased appetite	7	35
Sputum Production	1	5
Hemoptysis	1	5
Weight loss	2	10
Pain in Hemithorax	2	10
Odynophagia	1	5

**Table 3.** The frequency of bronchoscopic features in patients with endobronchial tuberculosis

Subtype	Number	Percentage
Fibrostenotic	4	20
Edematous-hyperemic	5	25
Caseous Necrosis	6	30
Anthracosis edema	10	50
Tumorous	5	25
Granular	0	0
Ulcerative	1	5
Nonspecific bronchitis	1	5

**Figure 1.** Common features of endobronchial tuberculosis as anthracosis in 55% (A), caseous necrosis in 30% (B), edematous-hyperemic in 25% (C)



Among the 11 patients with a determined ESR, 9 cases had ESR of more than the upper limit of the normal range according to their age (ranging between 50 and 130 mm/hour). Only in one case ESR was 20 mm/hour.

Among the 15 patients whose chest X-rays were available, pulmonary consolidation (75%), reduced pulmonary volume (20%) and unilateral or bilateral hilum adenopathy (10%) were the most common findings.

## Discussion

In several studies, EBTB was reported to be more common in males (5, 6), whereas in some others, including ours, it was more prevalent among females. In Bekci et al. study, most patients with anthracofibrosis were elderly women with no occupational and smoking history (7).

Cough was the most common symptom in the great majority of studies, which can be accompanied without dyspnea or systemic symptoms (6, 7).

Lung opacity, collapse and reduced volume were the common radiologic signs in the most studies, which can occur during an active infection or years later. Given the possibility of a negative sputum smear and culture result, the absence of abnormality in the chest X-ray does not refute EBTB. Therefore, bronchoscopy, along with histologic and microbiologic assessments, is an essential tool for a definitive diagnosis (8, 9).

In a study carried out by Composa et al., granulomatous and ulcerative bronchitis were the most common findings, while active caseous (43%), mucosal edema and hyperemia (14%) were the most common findings in the Chung study. Moreover, Ozkaya et al. reported the edematous-hyperemic appearance (34.7%) as the most common pattern diagnosed in their patients' bronchoscopy examination. However, the nonspecific bronchitic feature, followed by mucosal edema and hyperemia, was the most common finding of the Samardzic et al. study. Among our studied patients, mucosal anthracosis (55%), followed by caseous necrosis (30%),

mucosal edema and hyperemia (25%), was most common observation. Nonspecific bronchitis had the least prevalence (5, 6, 8).

In the current study, endobronchial involvement without anthracosis was located on the left side in all the cases, while the most common involvement pattern with anthracosis is the bilateral type. In a study performed by Kim, right pulmonary involvement, mainly in the right middle lobe was more common in the bronchoanthracofibrosis group, as compared to the non-anthracosis group (8).

Fibrostenosis, which was found in 20% of our patients, can lead to resistant tuberculosis making the patients a reservoir for disease transmission. Moreover, it increases the probability of pulmonary complications and death (10).

Although anthracosis was the most common bronchoscopic finding among our patients, it was not observed in those less than 60 years of age. Ghanei et al. conducted a study with a large sample size (919 cases), it was found that only 5% of those with anthracosis were younger than 40 years, and its prevalence increased with advancing age, for this reason it is considered as an elderly's disease (11).

The majority of the infected cases in our study were housewives. Therefore, occupational exposure cannot be a risk factor for anthracosis. Considering the fact that 61.5% of the affected cases in Ghanei et al. study did not have any occupational exposure, its presence was strongly suggested to be related to an active or old TB infection. Bekci et al. have suggested biopsy during bronchoscopy and examining the sample for tuberculosis in all the patients with anthracosis to be essential. Baking bread in the traditional way is an occupational risk factor for EBTB. Considering the prevalence of EBTB in this profession, examining the suspicious cases for TB is of great importance (7, 11).

In Ghanei et al., as well as our study, which were conducted in Iran, a developing country and an endemic region for TB, anthracosis and high ESR were common among TB patients. These findings can confirm the finding of Ghanei et al.

study suggesting that empirical anti-tuberculosis therapy is required in symptomatic patients with bronchial anthracosis and an ESR>100, especially when anthracosis is limited to one lung or when in addition to this condition, cavitory lesions are also present in the chest X-ray. The improvement of endobronchial anthracofibrosis lesions following a 6-month anti-TB therapy regimen is a clear indicator of their association (12).

Mirsadraee et al. investigated the association between anthracosis and tuberculosis. It was found that in all the anthracosis patients the prevalence of tuberculosis was higher than the control group, confirming the association between tuberculosis and anthracosis (13).

In the present study, none of the patients had cavitory lesions. This finding was in agreement with the Golshan study performed in 2002. It seems that EBTB is the result of direct implantation of tubercle bacilli into the bronchus (4). However, cavities were present in 60.4% of patients in the Samardzic et al. study performed in Belgrade (6).

In EBTB the sputum smear should be negative for AFB in many cases, which was the case for the majority of our patients, resulting in a delayed or incorrect diagnosis. Therefore, a negative mucosal test does not rule out the possibility of EBTB, because mucosal lesion may be need for positive smear results or proximal bronchial stenosis by a lesion or disturbance in mucosal removal may cause negative smear testing (8, 10).

In general, there were certain limitations in our study. As the study population was not large enough, subtype comparisons could not be performed. Furthermore, since this was a retrospective study, some data might have been lost during time.

Given the fact that TB is an endemic disease in many countries including Iran, and persistent cough is one of apparent symptoms, even with a normal chest X-ray and a negative sputum smear test for AFB, EBTB should be suspected. To prevent outbreak of this disease, in case of clinical suspicion, applying differential diagnosis methods and performing bronchoscopy are necessary in order to confirm or refute the diagnosis. Taking such precautionary measures would result in early diagnosis, timely and appropriate treatment, fewer complications and reduced disease transmission in the community.

## Acknowledgements

Authors would like to thank the nursing staff of bronchoscopy unit of Imam Reza Hospital.

## Conflict of Interest

The authors declare no conflict of interest.

## References

1. Corbett EL, Watt CJ, Walker N, Maher D, Williams BG, Raviglione MC, et al. The growing burden of tuberculosis: global trends and interactions with the HIV epidemic. *Arch Intern Med.* 2003; 163:1009-21.
2. World Health Organization. Estimates of TB and MDR-TB burden are produced by WHO in consultation with countries; 2015.
3. Tamura A, Hebisawa A, Masuda K, Shimada M, Kunogi M, Kaneko Y, et al. Features of bronchial tuberculosis-an-analysis of 103 cases. *Kekkaku.* 2007; 82:647-54.
4. Golshan M. Tuberculosis bronchitis with normal chest x-ray among a large bronchoscopic population. *Ann Saudi Med.* 2002; 22:98-101.
5. Miguel Campos E, Puzo Ardanuy C, Burgués Mauri C, Castella Riera J. A study of 73 cases of bronchial tuberculosis. *Arch Bronconeumol.* 2008; 44:282-4.
6. Samardzić N, Jovanović D, Marković-Denić L, Roksandić-Milenković M, Popević S, Skodrić-Trifunović V. Clinical features of endobronchial tuberculosis. *Vojnosanit Pregl.* 2014; 71:156-60.
7. Bekci TT, Maden E, Emre L. Bronchial anthracofibrosis case with endobronchial tuberculosis. *Int J Med Sci.* 2011; 8:84-7.
8. Ozkaya S, Bilgin S, Findik S, Kök HC, Yuksel C, Atıcı AG. Endobronchial tuberculosis: histopathological subsets and microbiological results. *Multidiscip Respir Med.* 2012; 7:34.
9. Chung HS, Lee JH. Bronchoscopic assessment of the evolution of endobronchial tuberculosis. *Chest.* 2000; 117:385-92.
10. Kim HJ, Kim SD, Shin DW, Bae SH, Kim AL, Kim JN, et al. Relationship between bronchial anthracofibrosis and endobronchial tuberculosis. *Korean J Intern Med.* 2013; 28:330-8.
11. Xue Q, Wang N, Xue X, Wang J. Endobronchial tuberculosis: an overview. *Eur J Clin Microbiol Infect Dis.* 2011; 30:1039-44.
12. Ghanei M, Aslani J, Peyman M, Ahmadzad Asl M, Pirnazar O. Bronchial anthracosis: a potent clue for diagnosis of pulmonary tuberculosis. *Oman Med J.* 2011; 26:19-22.
13. Mirsadraee M, Saffari A, Sarafraz Yazdi M, Meshkat M. Frequency of tuberculosis in anthracosis of the lung: a systematic review. *Arch Iran Med.* 2013; 16:661-4.